

Letter to the Editor**Parvovirus B19 Infection in a Patient with Common Variable Immunodeficiency****Keywords:** Parvovirus B19; Immunodeficiency; Bone marrow; Megaloblasts.**Published:** March 1, 2021**Received:** January 30, 2021**Accepted:** February 14, 2021**Citation:** Zanelli M., Ruggeri L., Sanguedolce F., Zizzo M., Martino G., Genua A., Ascani S. *Parvovirus B19 infection in a patient with common variable immunodeficiency.* *Mediterr J Hematol Infect Dis* 2021, 13(1): e2021026, DOI: <http://dx.doi.org/10.4084/MJHID.2021.026>

This is an Open Access article distributed under the terms of the Creative Commons Attribution License (<https://creativecommons.org/licenses/by-nc/4.0>), which permits unrestricted use, distribution, and reproduction in any medium, provided the original work is properly cited.

To the editor.

We read with great interest the paper by Urio *et al.* reporting on prevalence and factors associated with Human *Parvovirus B19* infection in sickle cell patients hospitalized in Tanzania.¹ People with frequent episodes of hemolytic anemia, including sickle cell disease, are at increased risk of *Parvovirus B19* infection as well as immunocompromised patients¹.

We report the case of a 50-year-old woman with a few years history of common variable immunodeficiency (CVID), presenting with profound asthenia. The patient had previously declined immunoglobulin therapy due to the absence of infective episodes. Few days before admission, she had a fever following the meningococcal vaccine. On admission, the patient was afebrile. Splenomegaly (16 cm in maximum diameter) was present in the absence of lymphadenopathy. Laboratory tests revealed anemia (Hb 7.5 g/dl) with low reticulocyte count (0.1%, normal adult range 0.5% to 2.5%). Serum electrophoresis confirmed hypogammaglobulinemia (IgG 519 mg/dl, normal range 700-1600 mg/dl; IgA 46 mg/dl, normal range 70-400; IgM 20 mg/dl, normal range 40-280 mg/dl). Lactate dehydrogenase (LDH) level was elevated (594 UI/L). Coombs test was negative. B12 vitamin and folate were within normal values. Serologic tests for Hepatitis B and Hepatitis C virus, Human Immunodeficiency Virus (HIV), and *Parvovirus B19* were negative, as well as rheumatoid factor and antinuclear antibodies.

Bone marrow biopsy showed a normocellular marrow with a reduced erythroid lineage relative to the overall intact granulopoiesis. The erythropoiesis was almost completely made up of large-sized proerythroblasts (so-called megaloblasts) with vesicular chromatin and a subtle nuclear membrane (**Figure 1**). Megakaryocytes were slightly increased in number with nuclear lobulation defects. Cytogenetic analysis revealed a normal karyotype. Bone marrow aspirate confirmed the presence of giant proerythroblasts with

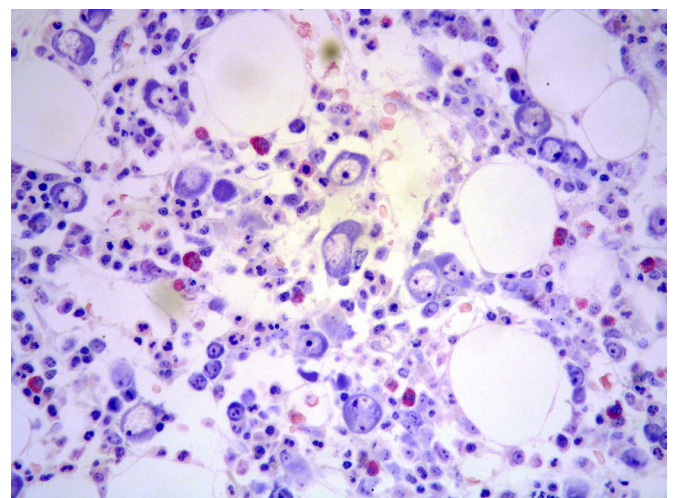


Figure 1. Bone marrow biopsy showing large proerythroblasts with dispersed chromatin and subtle nuclear membrane (HE x400 magnification).

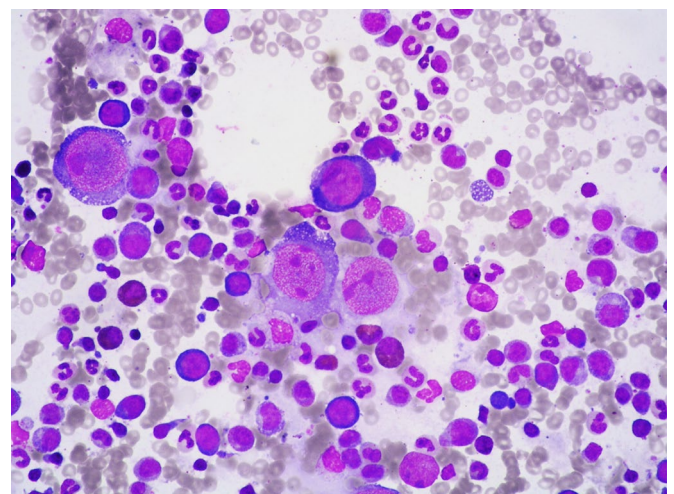


Figure 2. Bone marrow aspirate highlighting giant proerythroblasts with cytoplasmic vacuoles.

cytoplasmic vacuoles (**Figure 2**). The marrow findings were suggestive of *Parvovirus B19* infection. In our patient, *Parvovirus B19* serology was negative. However, polymerase chain reaction (PCR) detected

Parvovirus B19 DNA (556,936 viral copies) on peripheral blood. Prompt treatment with intravenous immunoglobulins (400/mg/kg for five days) was started with progressive anemia resolution and a marked decrease of viral DNA copies. Because of the infective episode, treatment with subcutaneous immunoglobulins was continued indefinitely. The patient is well, with no other infective episode at about three years from *Parvovirus* B19 infection.

Human *Parvovirus* B19 (HPV-B19) is the only member of the *Parvoviridae* family known to be pathologic in humans.² It is classified as a member of the *Erythroparvovirus* genus due to its unique high tropism to red blood cell precursors, leading to temporary bone marrow infection and transient erythropoiesis arrest.³ The clinical manifestations of HPV-B19 infection depend on the host's age and hematological and immunological status. In adults, the viremic period is generally characterized by low hemoglobin level, with reticulocytes disappearance associated with fever, arthralgia, and malaise. The clinical manifestation is usually self-limited in healthy individuals developing specific anti-virus antibodies. Sickle cell disease patients, as reported in the paper by Urio *et al.*,¹ have a high risk of infection due to the increase in red blood cells precursor division, that sickle cell patients have to compensate for the deficiency of circulating red blood

cells. In the setting of immunodeficiency, as in CVID patients unable to develop a specific immune response neutralizing the virus, there is a persistent viremia, and the clinical manifestation is usually aplastic anemia, although cases presenting as polyarticular arthritis are reported.^{2,4,5} Acute *Parvovirus* B19 infection should be suspected in patients with immunologic diseases presenting with reticulocytopenic anemia. It is worth mentioning that in immunocompromised individuals, as in our patient, *Parvovirus* B19 serology can be negative, because of the reduced capacity to develop an antibody response.⁵ In these patients, PCR analysis of *Parvovirus* B19 is essential to achieve the correct diagnosis and set the appropriate therapy. Immunoglobulin replacement could result in clearance of viremia, as it was in our patient.⁶

Ethics approval and consent to participate. All procedures performed in studies involving human participants were in accordance with the ethical standards of the institutional and/or national research committee and with the 1964 Helsinki Declaration and its later amendments or comparable ethical standards.

The patient signed an informed consent form and agreed to publication.

Magda Zanelli¹, Loredana Ruggeri², Francesca Sanguedolce³, Maurizio Zizzo^{4,5,*}, Giovanni Martino², Angelo Genua⁶ and Stefano Ascani⁷.

¹ Pathology Unit, Azienda Unità Sanitaria Locale-IRCCS di Reggio Emilia, 42122 Reggio Emilia, Italy.

² Hematology Unit, CREO, Azienda Ospedaliera di Perugia, University of Perugia, 06123 Perugia, Italy.

³ Pathology Unit, Azienda Ospedaliero-Universitaria-Ospedali Riuniti di Foggia, 71122 Foggia, Italy.

⁴ Surgical Oncology Unit, Azienda Unità Sanitaria Locale-IRCCS di Reggio Emilia, 42122 Reggio Emilia, Italy.

⁵ Clinical and Experimental Medicine PhD Program, University of Modena and Reggio Emilia, 41121 Modena, Italy.

⁶ Oncohematology Unit, Azienda Ospedaliera S. Maria di Terni, University of Perugia, 05100 Terni, Italy.

⁷ Pathology Unit, Azienda Ospedaliera S. Maria di Terni, University of Perugia, 05100 Terni, Italy.

Competing interests: The authors declare no conflict of Interest.

Correspondence to: Maurizio Zizzo, Surgical Oncology Unit, Azienda Unità Sanitaria Locale-IRCCS di Reggio Emilia, Viale Risorgimento, 80, 42123 Reggio Emilia, Italy. Tel: +39-0522-296372, fax: +39-0522-295779. E-mail: zizzomaurizio@gmail.com

References:

1. Urio F, George H, Tluway F, Nyambo TB, Mmbando BP, Makani J. Prevalence and Factors Associated with Human Parvovirus B19 Infection in Sickle Cell Patients Hospitalized in Tanzania. *Mediterr J Hematol Infect Dis*. 2019;11(1):e2019054. <https://doi.org/10.4084/mjhid.2019.054> PMID:31528320 PMCID:PMC6736168
2. Peterlana D.; Puccetti A.; Corrocher R.; Lunardi C. Serologic and molecular detection of human Parvovirus B19 infection. *Clin Chim Acta* 2006, 372, 14-23. <https://doi.org/10.1016/j.cca.2006.04.018> PMID:16765338
3. Heegaard H.D.; Brown K.E. Human parvovirus B19. *Clin Microbiol Rev* 2002, 15, 485-505. <https://doi.org/10.1128/CMR.15.3.485-505.2002> PMID:12097253 PMCID:PMC118081
4. Adams S.T.M.; Schmidt K.M.; Cost M.K.; Marshall G.S. Common variable immunodeficiency presenting with persistent parvovirus B19 infection. *Pediatrics* 2012, 130, e1711-5. <https://doi.org/10.1542/peds.2011-2556> PMID:23129076
5. Ruiz Gutiérrez L.; Albarrán F.; Moruno H.; Cuende E. Parvovirus B19 chronic monoarthritis in a patient with common variable immunodeficiency. *Reumatol Clin* 2015, 11, 56-59. <https://doi.org/10.1016/j.reuma.2014.07.001> PMID:25441493
6. Chuhjo T.; Nakao S.; Matsuda T. Successful treatment of persistent erythroid aplasia caused by Parvovirus B19 infection in a patient with common variable immunodeficiency with low-dose immunoglobulin. *Am J Hematol* 1999, 60, 222-224. [https://doi.org/10.1002/\(SICI\)1096-8652\(199903\)60:3<222::AID-AJH9>3.0.CO;2-K](https://doi.org/10.1002/(SICI)1096-8652(199903)60:3<222::AID-AJH9>3.0.CO;2-K)

