

Images in Hematology and Infectious Diseases

Caries Spine Presenting as Thyroid and Multiple Paraspinal Abscesses

Adnan Agha, Mohammad Awad AlHumaidi and Abdelhaleem Bella

Department of Internal Medicine, King Fahad Hospital, Armed Forces Hospital Program Southern Region, Khamis Mushyt, P.O. Box 101, Kingdom of Saudi Arabia

Published: May 4, 2010

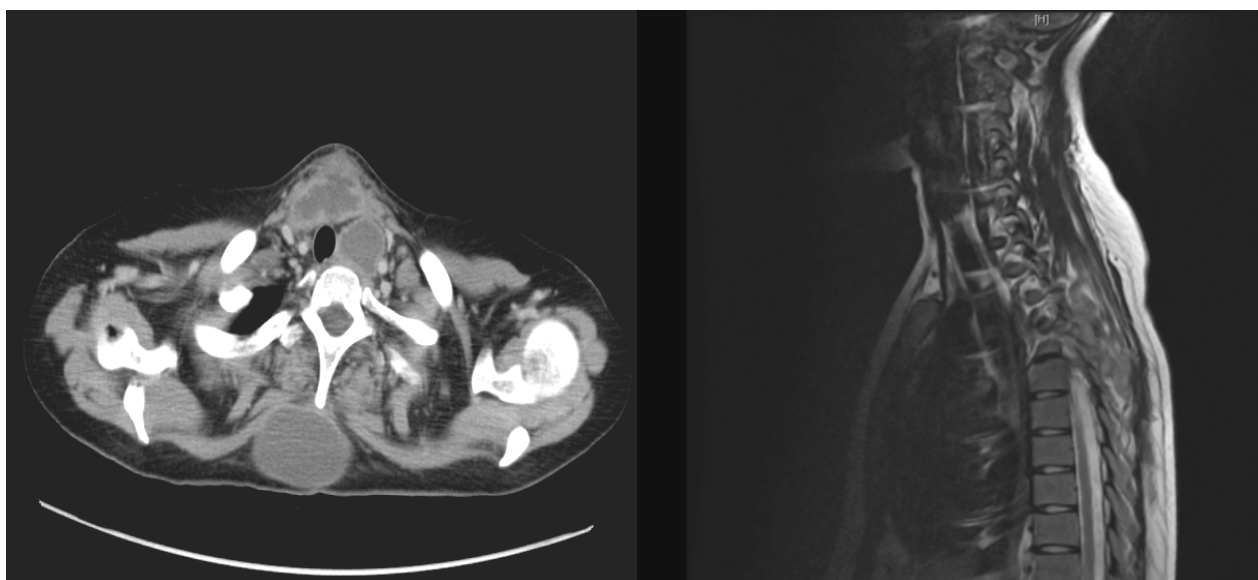
Received: April 25, 2010

Accepted: April 26, 2010

Mediterr J Hematol Infect Dis 2010, 2(1): e2010008, DOI 10.4084/MJHID.2010.008

This article is available from: <http://www.mjhid.org/article/view/5893>

This is an Open Access article distributed under the terms of the Creative Commons Attribution License (<http://creativecommons.org/licenses/by/2.0>), which permits unrestricted use, distribution, and reproduction in any medium, provided the original work is properly cited



Description: This 21 years old women presented consecutive cough with sputum and intermittent high grade fever all through her last trimester of pregnancy. On examination she was sick looking, febrile, and having bilateral lower limb weakness with spasticity and positive ankle clonus. She also had multiple swelling over upper back and neck without redness or hotness over it. The patient was admitted. The subsequent CT scan of the neck is

significant for multiple cold abscesses all over body with one visible in the thyroid gland and one compressing on the thoracic spine. The cold abscesses were drained and spine decompression surgery was done. The patient was started on 4-drug regimen of anti-tuberculosis therapy and is now without complaints or any residual abscesses after four months.