

## Review Articles

### **Cerebral Venous Thrombosis in the Mediterranean Area in Children**

S. Menascu<sup>1</sup>, A. Lotan<sup>2,3</sup>, B. Ben Zeev<sup>1</sup>, U. Nowak-Gottl<sup>4</sup> and G. Kenet<sup>3</sup>

<sup>1</sup>Department of Pediatric Neurology, The Edmond and Lily Safra Children's hospital, Sheba Medical Center, Tel Hashomer and the Sackler Medical School, Tel Aviv University, Israel

<sup>2</sup>Department of Pediatrics, E Wolfson Medical Center, Holon and the Sackler Medical School, Tel Aviv University, Israel

<sup>3</sup>Thrombosis Unit, The national Hemophilia center, Sheba Medical Center, Tel Hashomer and the Sackler Medical School, Tel Aviv University, Israel

<sup>4</sup>Universitätsklinikum Schleswig-Holstein, Rechtsfähige Anstalt des öffentlichen Rechts der Christian-Albrechts-Universität zu Kiel und der Universität zu Lübeck, Germany

Correspondence to: G Kenet, MD. Director, Thrombosis Unit, The National Hemophilia Center, Sheba Medical Center, Tel Hashomer 52621, Israel. Phone:+972-3-5302120, Fax:+972-3-5351806. E-mail: [Gili.kenet@sheba.health.gov.il](mailto:Gili.kenet@sheba.health.gov.il)

**Competing interests:** The authors have declared that no competing interests exist.

---

Published: July 8, 2011

Received: April 20, 2011

Accepted: June 12, 2011

Mediterr J Hematol Infect Dis 2011, 3: e2011029, DOI 10.4084/MJHID.2011.029

This article is available from: <http://www.mjhid.org/article/view/8458>

This is an Open Access article distributed under the terms of the Creative Commons Attribution License (<http://creativecommons.org/licenses/by/2.0>), which permits unrestricted use, distribution, and reproduction in any medium, provided the original work is properly cited.

**Abstract: Cerebral Venous Sinus (sinovenous) Thrombosis (CSVT) is a serious and rare disorder, increasingly recognized and diagnosed in pediatric patients. The etiology and pathophysiology has not yet been completely clarified, and unlike adults with CSVT, management in children and neonates remains controversial. However, morbidity and mortality are significant, highlighting the continued need for high-quality studies within this field. The following review will highlight aspects of CSVT in the mediteranian area in children.**

---

**Epidemiology:** The incidence of childhood CSVT varies between 0.4 and 0.7 per 100,000 children per year.<sup>1-3</sup> More than 40% of childhood CSVT occurs within the neonatal period, with an incidence of 2.6 per 100,000 children per year in one series.<sup>1</sup> Notably, these reported figures are probably underestimates of the true rate of CSVT occurrence, since neonates often present with nonfocal neurologic signs and symptoms, potentially leading to missed diagnosis.<sup>2</sup> Old imaging techniques, the variable anatomy of sinovenous channels and rapid recanalization are all factors which may contribute to underdiagnosis.<sup>4</sup> The annual incidence of sinus vein thrombosis among children in

the mediteranian area is not reported. Some case-series, cohort and case controlled multicenter studies are available from Lebanon, Turkey, France, Italy, Portugal and Israel.<sup>5-10</sup> CSVT incidence evaluated among children and neonates hospitalized in a tertiary medical center in Israel was as high as 2/10,000,<sup>11</sup> potentially due to selection bias, in a referral center with high clinical awareness and high index of suspicion that led towards early diagnosis and treatment of CSVT. The largest European CSVT cohort consisted of 396 children, prospectively studied and followed in order to assess the risk factors associated with thrombosis recurrence.<sup>12</sup>

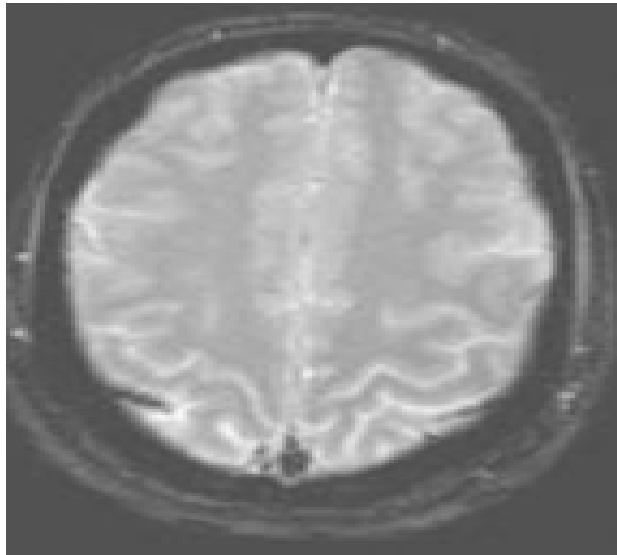
**Anatomy and Pathophysiology:** Cerebral vascular malformations may involve the venous circulation, with “developmental venous anomaly” (DVA) being the most frequent. This term, proposed by Lasjaunias et al.,<sup>13</sup> is now widely used as a synonym for venous angioma, cerebral venous malformation, or cerebral venous medullary malformation. DVAs are encountered with an incidence of up to 2.6% in a series of 4,069 brain autopsies.<sup>14</sup> They represent an anomalous venous disposition due to the absence of normal pial or subependymal veins. They may drain into both the superficial and deep venous systems, and a stenosis of the collecting vein of DVAs is commonly observed, typically at the point where the vein crosses the dura to drain into a dural venous sinus. The most frequently involved sites of CSVT are the superior sagittal sinus (90% of all cases in most studies) and transverse sinuses of the superficial venous system and the straight sinus of the deep system.<sup>15</sup> After CSVT, venous pressure escalates in the occluded vessels and secondary hemorrhagic infarction develops due to brain tissue hypertension, localized venous congestion, vasogenic edema, and increased capillary hydrostatic pressure in excess of cerebral arteriolar blood flow. Approximately 65% of neonates with CSVT have brain parenchymal lesions, frequently detected in the frontal and parietal lobes.<sup>16</sup>

**Clinical Presentation and Symptoms:** It is apparent that the clinical manifestations of CSVT are non-specific and may be subtle. Clinical scenarios occur at all ages and the clinician should consider this diagnosis in a wide range of acute neurological presentations in childhood. These include seizures, coma, stroke, headache and increased intracranial pressure.<sup>17</sup> Common illnesses, eg: ear infections, meningitis, anaemia, diabetes and head injury, may lead to CSVT evolution, various clinical settings including sepsis, dehydration, renal failure, trauma, cancer and haematological disorders may precipitate.<sup>18</sup> Although presentation with pseudotumour cerebri has been well documented, there are few data on the prevalence of CSVT in otherwise unexplained hydrocephalus or in convulsive and non-convulsive seizures and status epilepticus.<sup>19</sup> It has been suggested that toddlers frequently present with seizures and focal signs, mainly hemiparesis, whereas older children present with headache and changes in mental status and seizures may be less common.<sup>20</sup> In a study of neonatal sinus vein thrombosis (52 neonates with a median gestational age of 39 weeks), symptoms developed at a median postnatal age of 1.5 days (range: 0 to 28 days) and consisted mainly of seizures (29 of 52).<sup>21</sup> Other presenting findings in neonates were apnea (17.3%),

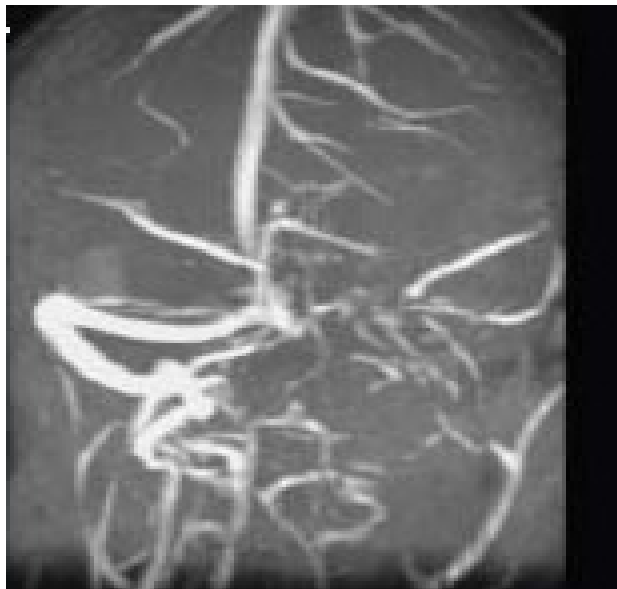agitation (5.8%), sepsis like(3.8%) and decreased consciousness in up to 2%.<sup>22</sup> The majority of young children present acutely with seizures, focal signs and symptoms of raised intracranial pressure, such as headache and decreased level of consciousness. Subacute presentation, with chronic headache, vomiting, lethargy, anorexia or drowsiness for 3 weeks or more, may also occur.<sup>23</sup>

**Diagnosis and Imaging Studies:** The clinical spectrum of CVST closely mimics that of idiopathic intracranial hypertension. Ultrasonography, which is the preliminary screening test for hemorrhage in the neonatal period, may detect intraventricular bleeding, centrally located venous infarcts or hemorrhages, and ventricular dilation and leukomalacia secondary to CSVT infarction and ischemia. However, ultrasound has poor sensitivity for cerebral infarction and should not be used for the primary detection of CSVT and the extent of ensuing injury.<sup>24,25</sup> Cranial computed tomography (CT) can be performed rapidly in neonates with minimum sedation but misses CSVT in 15% of cases. The classic features that indicate CSVT include the “dense triangle” or the “cord sign,” which describe the increased density over the thrombosed venous sinus in a plain CT, or the “empty triangle”<sup>26</sup> A communicating hydrocephalus may be associated with sagittal sinus thrombosis caused by the impaired CSF absorption over the arachnoid granulations that line the sagittal sinus. A CT venogram using the multislice technique is more sensitive and specific for the diagnosis of CSVT, but the consequent radiation exposure is a definite concern in neonates. MRI is free of radiation risk and permits earlier and more accurate detection of CSVT.<sup>27</sup> Diffusion-weighted imaging is a sensitive technique for detecting areas of infarction. Parenchymal changes can be seen within minutes of injury, which allows for early identification and intervention and Magnetic resonance venography allows for noninvasive assessment of the venous system without exposure to radiograph radiation. Using time-offlight techniques, the cerebral sinuses can be imaged even without the use of contrast. Currently, contrast-enhanced magnetic resonance venography, which is less susceptible to alterations in flow, is the imaging technique of choice for the detection of CSVT in the neonatal population.<sup>28</sup> Attached are 2 representative MR figures of CSVT in pediatric patients (**Figures 1,2**).

**Etiology and risk factors:** The etiology and pathophysiology of CSVT in the pediatric population is still poorly understood, and the role of thrombophilic



**Figure 1:** Cranial MRI- demonstrating occlusion of the sagittal sinus thrombosis.



**Figure 2:** Cranial MRV- demonstrating occlusion of the left transverse and sigmoid sinuses.

risk factors remains to be elucidated.<sup>1-5,10-12,29-30</sup> Trauma, infections (especially sinusitis, mastoiditis and other conditions affecting the head and neck area), collagen vascular disorders, hemoglobinopathies, metabolic and inflammatory bowel diseases have been suggested as potential risk factors for CSVT occurrence in small cohort and case study series.<sup>31-38</sup> Several case-control studies have dealt with the role of prothrombotic risk factors in the pathophysiology of CSVT.<sup>1-5,10-12,39-44</sup> In a recent meta-analysis of pediatric case-controlled studies thrombophilia certainly increased the risk of stroke or CSVT in patients aged 0-18 years old, especially when combination of thrombophilic risk factors was diagnosed.<sup>45</sup> A statistically significant association with first event

occurrence was demonstrated for each thrombophilia trait evaluated, with no difference found between arterial ischemic stroke and CSVT. Summary ORs (fixed-effects model) were as follows: antithrombin deficiency, 7.06 (95% CI, 2.44 to 22.42); protein C deficiency, 8.76 (95% CI, 4.53 to 16.96); protein S deficiency, 3.20 (95% CI, 1.22 to 8.40), factor V G1691A, 3.26 (95% CI, 2.59 to 4.10); factor II G20210A, 2.43 (95% CI, 1.67 to 3.51); MTHFR C677T (AIS), 1.58 (95% CI, 1.20 to 2.08); antiphospholipid antibodies (AIS), 6.95 (95% CI, 3.67 to 13.14); elevated lipoprotein(a), 6.27 (95% CI, 4.52 to 8.69), and combined thrombophilias, 11.86 (95% CI, 5.93 to 23.73). Genetic thrombophilia, and especially presence of prothrombin G20210A mutation significantly increase the risk of recurrent thromboembolism in CSVT patients older than 2 years of age,<sup>12</sup> in situations of future acquired hypercoagulability.

**Outcome:** Over all neonates have a more favorable outcome as compared to older children.<sup>46</sup> Nevertheless, in the majority of studies the authors did not adequately describe outcomes in neonates compared with those of children with CSVT. The mean age of follow-up varied across the studies, and disabilities were variably classified.<sup>47</sup> Currently, there is a substantial differences in reporting the correct neurodevelopment outcome of neonates and children with CSVT, mainly due to lack of standardized assessment protocols. Neurologic deficits including epilepsy, motor impairments, and a range of cognitive impairments were reported for 10% to 80% of all neonates on follow up. Wasay et al<sup>48</sup> reported a higher mortality rate from CSVT in neonates, significantly associated with coma and seizures occurring at presentation. Other predictors of poor neurologic outcome were coagulation abnormalities, multiple sinus thrombosis, seizures at presentation, and venous infarction.<sup>49-50</sup> Notably, CSVT prognosis was found to be better when compared to arterial ischemic stroke.<sup>51-52</sup> Nearly 50% of CSVT patients do not have infarcts and may suffer fewer motor deficits or no permanent damage.<sup>53</sup>

**Therapy:** There are no evidence based recommendations for the therapy of thrombosis in children due to the lack of randomized controlled trials.<sup>54</sup> The aim of antithrombotic therapy after CSVT is vascular patency, mitigation of thrombus growth and the avoidance of a new thrombosis in the phase of secondary prophylaxis after the acute treatment period. Therapy outcome in children differs. This is in part due to the absence of controlled trials with comparable end points. Although not treating CSVT may significantly

increase the risk of thrombus propagation that is associated with new venous infarctions and worse clinical outcomes, safety issues should be considered.

Whereas in adults anticoagulant therapy of CSVT is recommended,<sup>55</sup> such therapy is currently less obvious for children and neonates.<sup>56</sup> A recent multi-center Portuguese study reported no influence of anticoagulation upon CSVT outcome.<sup>57</sup> However, in a single center pediatric CSVT cohort, Mahendranath et al describe a rate of 6% treatment related hemorrhage and a 31% rate of thrombus propagation in untreated patients.<sup>58</sup>

Notably, prospective follow up of the European pediatric CSVT cohort reflected the need for secondary anticoagulant prophylaxis in future high risk situations, especially in children with thrombophilia and lack of thrombus recanalization following acute phase

therapy.<sup>12</sup> Pediatric hematology expert groups recommend tailored therapy regimens based upon patient's condition, combinations of risk factors and presumed recurrence risk.<sup>59-61</sup>

Thrombolytic therapy is generally limited to severe cases with a high risk of mortality.<sup>62-64</sup>

Generally, disease severity would be associated with antithrombotic treatment, especially in non-neonates. Markers of severity may include presentation with diffuse signs/ massive extended thrombosis or altered level of consciousness. Children with congenital or acquired heart disease require heparinization. The presence of thrombophilia and lack of transient risk factors (namely: idiopathic CSVT) determines the need for prolonged anticoagulant therapy.

## References:

- Heller C., Heinecke A., Junker R. Cerebral venous thrombosis in children: a multifactorial origin. *Circulation*. 2003;108:1362–1367. doi:10.1161/01.CIR.0000087598.05977.45 PMID:12939214
- deVeber G., Andrew M. The Canadian Paediatric Ischemic Stroke Study group. The epidemiology and outcome of sinovenous thrombosis in pediatric patients. *N Engl J Med*. 2001;345:417–423. doi:10.1056/NEJM200108093450604 PMID:11496852
- Lynch J.K., Nelson K.B. Epidemiology of perinatal stroke. *Curr Opin Pediatr*. 2001;13:499–505. doi:10.1097/00008480-200112000-00002 PMID:11753097
- Dlamini N, Billingham L, Kirkham FJ. Cerebral venous sinus thrombosis in children. *Neurosurg Clin N Am* 2010;21: 511-27. doi:10.1016/j.neu.2010.03.006 PMID:20561500 PMCID:2892748
- Otrock ZK, Taher AT, Shamseddeen WA, Mahfouz RA. Thrombophilic risk factors among 16 Lebanese patients with cerebral venous and sinus thrombosis. *J Thromb Thrombolysis*. 2008;26:41-3. doi:10.1007/s11239-007-0093-x PMID:17823778
- Teksam M, Moharir M, Deveber G, Shroff M. Frequency and topographic distribution of brain lesions in pediatric cerebral venous thrombosis *AJNR Am J Neuroradiol*. 2008;29:1961-5. doi:10.3174/ajnr.A1246 PMID:18687742
- Barbosa M, Mahadevan J, Weon YC, Yoshida Y, Ozanne A, Rodesch G, Alvarez H, Lasjaunias P. Dural Sinus Malformations (DSM) with Giant Lakes, in Neonates and Infants. Review of 30 Consecutive Cases. *Interv Neuroradiol*. 2003;9:407-24. PMID:20591322
- Buccino G, Cossu G, De Fanti A, Manotti C, Izzi GC, Mancina D. Cerebral venous sinus thrombosis in childhood: clinical aspects and neurological and cognitive long-term outcome in three cases. *Neurol Sci*. 2004;25:296-300. doi:10.1007/s10072-004-0357-6 PMID:15624088
- Vieira JP, Luis C, Monteiro JP, Temudo T, Campos MM, Quintas S, Nunes S. Cerebral sinovenous thrombosis in children: clinical presentation and extension, localization and recanalization of thrombosis. *Eur J Paediatr Neurol*. 2010;14:80-5. doi:10.1016/j.ejpn.2008.12.004 PMID:19201633
- Kenet G, Waldman D, Lubetsky A, Kornbrut N et al. Paediatric cerebral sinus vein thrombosis. A multi-center, case-controlled study. *Thromb Haemost*. 2004; 92:713-8. PMID:15467900
- Waldman D, Manashku S, Strauss T, Goldstein G, Ben-Zeev B, Kenet G. Thrombophilia and thrombosis in children--lessons from cerebral sinus vein thrombosis registry of a tertiary center. *Harefuah*. 2010;149:270-3. 337. PMID:20929064
- Kenet G., Kirkham F., Niederstadt T. et al. Risk factors for recurrent venous thromboembolism in the European collaborative paediatric database on cerebral venous thrombosis: a multicentre cohort study. *Lancet Neurol*. 2007;6:595–603 doi:10.1016/S1474-4422(07)70131-X
- Lasjaunias P, Burrows P, Planet C . Developmental venous anomalies (DVA): the so-called venous angioma. *Neurosurg Rev*. 1986;9:233–42. doi:10.1007/BF01743138 PMID:3550523
- Lai PH, Chen PC, Pan HB, Yang CF. Venous infarction from a venous angioma occurring after thrombosis of a drainage vein. *AJR Am J Roentgenol* 1999;172:1698–99. PMID:10350326
- Sarwar M, McCormick WF. Intracerebral venous angioma. Case report and review. *Arch Neurol*. 1978;35:323–25. PMID:646686
- San Millan Ruiz D, Delavelle J, Yilmaz H, Gailloud P, Piovan E, Bertramello A, Pizzini F, Rufenacht DA. Parenchymal abnormalities associated with developmental venous anomalies. *Neuroradiology*. 2007;49:987–95. doi:10.1007/s00234-007-0279-0 PMID:17703296
- Fitzgerald KC, Williams LS, Garg BP, Carvalho KS, Golomb MR. Cerebral sinovenousthrombosis in the neonate. *Arch Neurol*. 2006;63:405–9. doi:10.1001/archneur.63.3.405 PMID:16533968
- Barron TF, Gusnard DA, Zimmerman RA, Clancy RR. Cerebral venous thrombosis in neonates and children. *Pediatr Neurol*. 1992;8:112–16. doi:10.1016/0887-8994(92)90030-3
- Wu YW, Miller SP, Chin K, et al. Multiple risk factors in neonatal sinovenous thrombosis. *Neurology*. 2002;59:438–40. PMID:12177381
- Carvalho KS, Bodensteiner JB, Connolly PJ, Garg BP. Cerebral venous thrombosis in children. *J Child Neurol*. 2001;16:574 –80. PMID:11510928
- Hunt RW, Badawi N, Laing S, Lam A. Preeclampsia: a predisposing factor for neonatal neonatal venous sinus thrombosis? *Pediatr Neurol*. 2001;25:242–6. doi:10.1016/S0887-8994(01)00291-0
- Newton TH, Gooding CA. Compression of superior sagittal sinus by neonatal calvarial molding. *Radiology*. 1975;115:635–40. PMID:1129476
- Heller C, Heinecke A, Junker R, et al; Childhood Stroke Study Group. Cerebral venous thrombosis in children: a multifactorial origin. *Circulation*. 2003;108:1362–7. doi:10.1161/01.CIR.0000087598.05977.45 PMID:12939214
- Kersbergen KJ, de Vries LS, van Straaten HL, Benders MJ, Nieuvelstein RA, Groenendaal F. Anticoagulation therapy and imaging in neonates with a unilateral thalamic hemorrhage due to cerebral sinovenous thrombosis. *Stroke*. 2009;40:2754–60. doi:10.1161/STROKEAHA.109.554790 PMID:19542053
- Lequin MH, Dudink J, Tong KA, Obenaus A. Magnetic resonance imaging in neonatal stroke. *Semin Fetal Neonatal Med*. 2009;14:299–310. doi:10.1016/j.siny.2009.07.005 PMID:19632909

26. Justich E, Lammer J, Fritsch G, Beitzke A, Walter GF. CT diagnosis of thrombosis of dural sinuses in childhood. *Eur J Radiol.* 1984;4:294–5. PMID:6519062
27. Nwosu ME, Williams LS, Edwards-Brown M, Eckert GJ, Golomb MR. Neonatal sinovenous thrombosis: presentation and association with imaging. *Pediatr Neurol.* 2008;39:155–61. doi:10.1016/j.pediatrneurol.2008.06.001 PMID:18725059
28. Widjaja E, Shroff M, Blaser S, Laughlin S, Raybaud C. 2D time-of-flight MR venography in neonates: anatomy and pitfalls. *AJNR Am J Neuroradiol.* 2006;27:1913–18. PMID:17032865
29. Uthman I, Khalil I, Sawaya R, Taher A. Lupus anticoagulant, factor V Leiden, and methylenetetrahydrofolate reductase gene mutation in a lupus patient with cerebral venous thrombosis. *Clin Rheumatol.* 2004;23:362–3.
30. Akbalik M, Duru F, Fisgin T, Tasdemir HA, Incesu L, Albayrak D, Ozyurek E. Cerebral thrombosis associated with heterozygous factor V Leiden mutation and high lipoprotein(a) level in a girl with factor XIII deficiency. *Blood Coagul Fibrinolysis.* 2007;18:371–4. doi:10.1097/MBC.0b013e3280d5a7be
31. Stiefel D, Eich G, Sacher P. Posttraumatic dural sinus thrombosis in children. *Eur J Pediatr Surg.* 2000;10:41–4. doi:10.1055/s-2008-1072321 PMID:10770246
32. Matsushige T, Nakaoka M, Kiya K. Cerebral sinovenous thrombosis after closed head injury. *J Trauma.* 2009;66:1599–604. doi:10.1097/TA.0b013e328181a3a8e6 PMID:19509620
33. Krishnan A, Kamad DR, Limaye U. Cerebral venous and dural sinus thrombosis in severe falciparum malaria. *J Infect.* 2004;48:86–90. doi:10.1016/S0163-4453(03)00130-0
34. Prasad R, Singh R, Joshi B. Lateral sinus thrombosis in neurocysticercosis. *Trop Doct.* 2005;35:182–3. doi:10.1258/0049475054620914 PMID:16105354
35. Standridge S., de los Reyes E. Inflammatory bowel disease and cerebrovascular arterial and venous thromboembolic events in 4 pediatric patients: a case series and review of the literature. *J Child Neurol.* 2008;23:59–66. doi:10.1177/0883073807308706 PMID:18184942
36. Uziel Y, Laxer RM, Blaser S. Cerebral vein thrombosis in childhood systemic lupus erythematosus. *J Pediatr.* 1995;126:722–7. doi:10.1016/S0022-3476(95)70399-3
37. Yoshimura S, Ago T, Kitazono T. Cerebral sinus thrombosis in a patient with Cushing's syndrome. *J Neurol Neurosurg Psychiatr.* 2005;76:1182–3. doi:10.1136/jnnp.2004.057315 PMID:50411
38. Siegert CE, Smelt AH, de Bruin TW. Superior sagittal sinus thrombosis and thyrotoxicosis. Possible association in two cases. *Stroke.* 1995;26:496–7. doi:10.1161/01.STR.26.3.496 PMID:7886732
39. Bonduel M, Sciuccati G, Hepner M. Factor V Leiden and prothrombin gene G20210A mutation in children with cerebral thromboembolism. *Am J Hematol.* 2003;73:81–6. doi:10.1002/ajh.10326 PMID:12749008
40. Cakmak S, Derex L, Berruyer M. Cerebral venous thrombosis: clinical outcome and systematic screening of prothrombotic factors. *Neurology.* 2003;60:1175–8. PMID:12682328
41. Johnson MC, Parkerson N, Ward S. Pediatric sinovenous thrombosis. *J Pediatr Hematol Oncol.* 2003;25:312–5. doi:10.1097/00043426-200304000-00009 PMID:12679646
42. Vorstman E, Keeling D, Leonard J. Sagittal sinus thrombosis in a teenager: homocystinuria associated with reversible antithrombin deficiency. *Dev Med Child Neurol.* 2002;44:498. doi:10.1111/j.1469-8749.2002.tb00314.x
43. Martinelli I, Battaglioli T, Pedotti P. Hyperhomocysteinemia in cerebral vein thrombosis. *Blood.* 2003;102:1363–6. doi:10.1182/blood-2003-02-0443 PMID:12714502
44. Cantu C, Alonso E, Jara A. Hyperhomocysteinemia, low folate and vitamin B12 concentrations, and methylene tetrahydrofolate reductase mutation in cerebral venous thrombosis. *Stroke.* 2004;35:1790–4. doi:10.1161/01.STR.0000132570.24618.78 PMID:15192249
45. Kenet G, Lütthoff LK, Albisetti M et al Impact of thrombophilia on risk of arterial ischemic stroke or cerebral sinovenous thrombosis in neonates and children: a systematic review and meta-analysis of observational studies. *Circulation* 2010;121:1838–47. doi:10.1161/CIRCULATIONAHA.109.913673 PMID:20385928
46. deVeber GA, MacGregor D, Curtis R, Mayank S. Neurologic outcome in survivors of childhood arterial ischemic stroke and sinovenous thrombosis. *J Child Neurol.* 2000;15:316–24. doi:10.1177/088307380001500508 PMID:10830198
47. S'bire G, Tabarki B, Saunders DE, et al. Cerebra venous sinus thrombosis in children: risk factors, presentation, diagnosis and outcome. *Brain.* 2005;128:477–89.
48. Wasay M, Dai AI, Ansari M, Shaikh Z, Roach ES. Cerebral venous sinus thrombosis in children: a multicenter cohort from the United States. *J Child Neurol.* 2008;23:26–31. doi:10.1177/0883073807307976 PMID:18184940
49. Johnson MC, Parkerson N, Ward S, de Alarcon PA. Pediatric sinovenous thrombosis. *J Pediatr Hematol Oncol.* 2003;25:312–5. doi:10.1097/00043426-200304000-00009 PMID:12679646
50. Jacobs K, Moulin T, Bogousslavsky J, Woimant F, Dehaene I, Tatu L. The stroke syndrome of cortical vein thrombosis. *Neurology.* 1996;47:376–82. PMID:8757007
51. De Schryver EL, Blom I, Braun KP, Kappelle LJ, Rinkel GJ, Peters AC, et al. Long-term prognosis of cerebral venous sinus thrombosis in childhood. *Dev Med Child Neurol.* 2004;46:514–9. doi:10.1111/j.1469-8749.2004.tb01008.x
52. de Bruijn SF, de Haan RJ, Stam J for the Cerebral Venous Sinus Thrombosis Study. Clinical features and prognostic factors of cerebral venous sinus thrombosis in a prospective series of 59 patients. *J Neurol Neurosurg Psychiatr.* 2001;70:105–8. doi:10.1136/jnnp.70.1.105 PMID:50411
53. Huisman TA, Holzmann D, Martin E, Willi UV. Cerebral venous thrombosis in childhood. *Eur Radiol* 2001;11:1760–5. doi:10.1007/s003300100822 PMID:11511899
54. Kersbergen KC, de Vries LS, van Straaten HLM. Anticoagulation therapy and imaging in neonates with a unilateral thalamic hemorrhage due to cerebral sinovenous thrombosis. *Stroke.* 2009;40:2754–60. doi:10.1161/STROKEAHA.109.554790 PMID:19542053
55. Stam J, de Bruijn SF, deVeber G. Anticoagulation for cerebral sinus thrombosis. *Cochrane Database Syst Rev.* 2002;4:CD002005. PMID:12519565
56. deVeber G., Chan A., Monagle P. Anticoagulation therapy in pediatric patients with sinovenous thrombosis: a cohort study. *Arch Neurol.* 1998;55:1533–7. doi:10.1001/archneur.55.12.1533 PMID:9865797
57. Viera JP, Luis C, Monteiro JP et al. Cerebral sinovenous thrombosis in children: clinical presentation and extension, localization and recanalization of thrombosis. *European Journal of Pediatric Neurology.* 2010;14:80–5. doi:10.1016/j.ejpn.2008.12.004 PMID:19201633
58. Mahendranath Moharir D, Shroff M, Stephens D et al. Anticoagulants in Pediatric Cerebral Sinovenous Thrombosis A Safety and Outcome Study. *Ann Neurol* 2010;67:590–9. PMID:20437556
59. Royal College of Physicians Paediatric Stroke Working Group. Stroke in Childhood: clinical guidelines for diagnosis, management and rehabilitation. Royal College of Physicians, London, November, 2004. Available at: [http://www.rcplondon.ac.uk/pubs/books/childstroke/childstroke\\_guidelines.pdf](http://www.rcplondon.ac.uk/pubs/books/childstroke/childstroke_guidelines.pdf)
60. Roach E.S., Golomb M.R., Adams R. Management of stroke in infants and children: a scientific statement from a Special Writing Group of the American Heart Association Stroke Council and the Council on Cardiovascular Disease in the Young. *Stroke.* 2008;39:2644–91. doi:10.1161/STROKEAHA.108.189696 PMID:18635845
61. Monagle P., Chalmers E., Chan A. Antithrombotic therapy in neonates and children: American College of Chest Physicians evidence-based clinical practice guidelines (8th edition) *Chest.* 2008;133:887S–968S. doi:10.1378/chest.08-0762 PMID:18574281
62. Griesemer DA, Theodorou AA, Berg RA. Local fibrinolysis in cerebral venous thrombosis. *Pediatr Neurol.* 1994;10:78–80. doi:10.1016/0887-8994(94)90075-2
63. Wasay M, Bakshi R, Kojan S. Nonrandomized comparison of local urokinase thrombolysis versus systemic heparin anticoagulation for superior sagittal sinus thrombosis. *Stroke.* 2001;32:2310–7. doi:10.1161/hs1001.096192 PMID:11588319

64. Ciccone A, Canhao P, Falcao F. Thrombolysis for cerebral vein and dural sinus thrombosis. Cochrane Database Syst Rev. 2004;1

CD003693. PMid:14974030