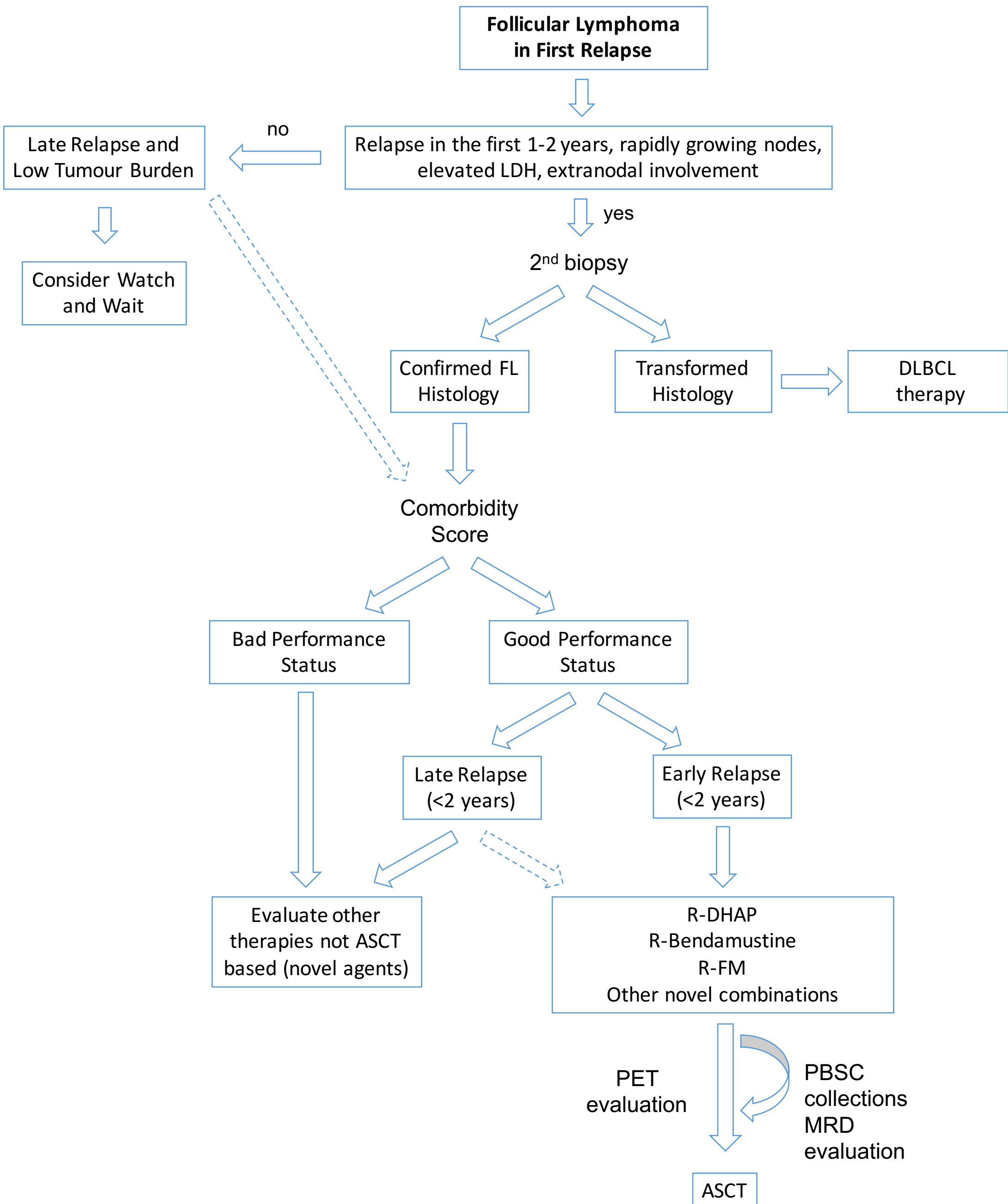

Follicular Lymphoma in First Relapse



Relapse in the first 1-2 years, rapidly growing nodes, elevated LDH, extranodal involvement

no



Late Relapse and Low Tumour Burden

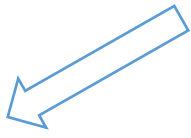


Consider Watch and Wait

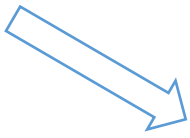


yes

2nd biopsy



Confirmed FL Histology



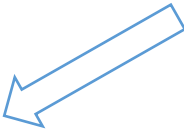
Transformed Histology



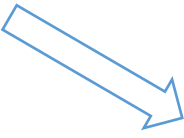
DLBCL therapy




Comorbidity Score



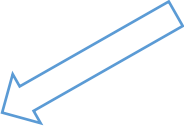
Bad Performance Status



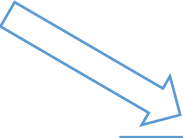
Good Performance Status



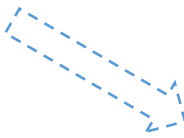
Evaluate other therapies not ASCT based (novel agents)



Late Relapse (<2 years)



Early Relapse (<2 years)



Evaluate other therapies not ASCT based (novel agents)



R-DHAP
R-Bendamustine
R-FM
Other novel combinations



PET evaluation



PBSC collections
MRD evaluation

ASCT