



Case Reports

Acquired von Willebrand Syndrome Associated to Secondary IgM MGUS Emerging after Autologous Stem Cell Transplantation for AL Amyloidosis

Hina Qamar¹, Adrienne Lee², Karen Valentine², Leslie Skeith² and Victor H Jimenez-Zepeda³

¹ Department of Medicine, University of Alberta, Edmonton, AB, Canada.

² Southern Alberta Rare Blood & Bleeding Disorders Comprehensive Care Program, Department of Medicine, Calgary, AB, Canada.

³ Tom Baker Cancer Center, Department of Medical Oncology and Hematology, Calgary, AB, Canada.

Competing interests: The authors have declared that no competing interests exist.

Abstract. Acquired von Willebrand syndrome (AVWS) is a rare hemorrhagic disorder that occurs in patients with no prior personal or family history of bleeding. Here, we describe a case of AVWS occurring after autologous stem cell transplantation (ASCT). Interestingly, AVWS developed after bortezomib-based induction and conditioning regimens. Recent evidence suggests that the proximity of the bortezomib therapy to the collection of stem cells with consequent depletion of regulatory T cells after the conditioning regimen could explain some of the unusual autoimmune complications reported in patients receiving bortezomib prior to ASCT. In addition, this patient developed a secondary MGUS post-ASCT, which may have also contributed to the AVWS. To the best of our knowledge, this is the first case of post-ASCT AVWS reported. Prospective data is needed to better elucidate the mechanisms by which these unusual complications occur in patients receiving bortezomib prior to ASCT.

Keywords: Amyloidosis, von Willebrand diseases, Hemorrhage, Paraproteinemia and Bortezomib.

Citation: Qamar H., Lee A., Valentine K., Skeith L., Jimenez-Zepeda V.H. Acquired von Willebrand Syndrome associated to secondary IgM MGUS emerging after autologous stem cell transplantation for AL amyloidosis. *Mediterr J Hematol Infect Dis* 2017, 9(1): e2017034, DOI: <http://dx.doi.org/10.4084/MJHID.2017.034>

Published: May 1, 2017

Received: February 15, 2017

Accepted: April 10, 2017

This is an Open Access article distributed under the terms of the Creative Commons Attribution License (<https://creativecommons.org/licenses/by-nc/4.0>), which permits unrestricted use, distribution, and reproduction in any medium, provided the original work is properly cited.

Correspondence to: Victor H Jimenez-Zepeda, MD. Tom Baker Cancer Center, 1331 29th St, NW, Calgary, AB, T2N 4N2. Tel. (403) 944-5246. E-mail: victor.zepeda@albertahealthservices.ca

Introduction. Immunoglobulin light-chain Amyloidosis (AL) is the most common type of systemic amyloidosis.¹ The use of high-dose chemotherapy followed by Autologous Stem Cell Transplantation (ASCT) has been recognized as an important therapy that has dramatically changed the perspective of AL amyloidosis care.² Since a plasma cell dyscrasia is the underlying cause of AL amyloidosis,³ ASCT has also been adopted for the treatment of this entity, aiming to induce a hematological and organ response by providing time for the involved organs to slowly clear out some of the amyloid protein that translates into

survival prolongation.⁴ Because the depth of response is a critical determinant of treatment outcome, different strategies have been employed, hoping to increase the proportion of patients who ultimately achieve a complete hematological response after ASCT. These strategies have included the use of induction chemotherapy before ASCT, especially for those patients with >10% bone marrow plasma cells.⁵ A recent, single-arm, prospective clinical trial investigated the role of bortezomib and dexamethasone induction followed by ASCT for newly diagnosed AL amyloidosis.⁶ The study was successful to show

unprecedentedly high hematologic responses. A hematologic very good partial response or better was seen in 77% of 35 patients at 6 months but was reported in 100% for the 27 patients who completed all planned therapy. While exciting results were noted, also new emerging complications after ASCT were seen (GVHD-like syndrome). The mechanisms by which this complication occurred remain uncertain. Here, we describe the first case of acquired von Willebrand syndrome (AVWS) in a patient with AL amyloidosis who received cyclophosphamide, bortezomib and dexamethasone induction followed by ASCT. Interestingly, this patient also developed a GVHD-like process in the skin that was successfully treated with steroids and a secondary IgM Monoclonal Gammopathy.

Case Presentation. A previously healthy, 56-year-old male presented with asymptomatic hypoalbuminemia detected on routine screening 2-years prior and subsequently developed asymmetric inflammatory polyarthritis (MCP's, wrists and shoulders) and proteinuria. Further investigations led to the diagnosis of AL Amyloidosis (Stage I) with a concurrent low-grade B-cell neoplasm on bone marrow and no evidence of lymphadenopathy. The patient presented mainly with kidney and soft tissue involvement. Pre-treatment studies revealed lambda light chain of 3030 mg/L (normal range 5.71-26.3), free kappa 59.3 mg/L (normal range 3.3-19.4) and ratio of 0.02 (normal range 0.26-1.65), 24 hr urine collection showed 9.86 g/day of proteinuria with 0.16 g/day of monoclonal IgG lambda and free lambda light chain. NT-pro-BNP and high-sensitive troponin-T were normal, serum LDH was normal, CRP was elevated (23.6 mg/L), creatinine was 108 μ mol/L, ALP was normal and hemostasis study was normal (PT, INR, PTT and factor X activity were all normal). Cardiac MRI and echocardiogram did not suggest amyloid involvement. Treatment with cyclophosphamide, bortezomib and dexamethasone (CyBorD) was initiated, achieving Very Good Partial Response (VGPR) after 3 cycles of therapy. Stem cell mobilization was successfully performed followed by autologous stem cell transplantation with bortezomib/melphalan conditioning. At-2 months post-ASCT the patient developed an erythematous rash affecting more than 50% of the body surface area. Skin biopsy was consistent with superficial

perivascular lymphocytic infiltrate. In addition, a new onset of moderate thrombocytopenia (platelet count of $45 \times 10^9/L$) was noted and a bone marrow biopsy was performed. BM biopsy showed normal cellularity and adequate megakaryocytes, no evidence of plasma or lymphoproliferative disorders were seen. Treatment with prednisone at 1mg/kg was initiated leading to complete resolution of these symptoms. At day-100, response assessment was consistent with complete hematologic response. Serum protein electrophoresis, however, showed the presence of a secondary IgM lambda Monoclonal Gammopathy. Four months post-ASCT patient presented to ER with prolonged epistaxis. Prior to this time, he has had no history of bleeding. Epistaxis was severe and required packing and cautery with mild improvement only. Laboratory investigations revealed prolonged PTT (45.5 s), and decrease von Willebrand factor activity (VWF:Act), von Willebrand factor antigen (VWF:Ag), and factor VIII activity (FVIII:C) levels. VWF:Act (GP1b) 12 IU/dL (normal range: 41-144), VWF:Ag 31 IU/dL (normal range: 40-185), FVIII:C 14 IU/dL (normal range: 54-147). Factor IX and XI levels were normal, FXII was slightly decreased at 30 IU/dL. Mixing studies for VWF:Act and FVIII:C showed no inhibitory effect on normal plasma consistent with a non-neutralizing VWF antibody against non-functional VWF domains. VWF propeptide to VWF antigen ratio (VWFpp:Ag) was increased at diagnosis (7.7) suggesting increased VWF clearance (VWFpp measured by VWFpp-specific monoclonal antibody enzyme-linked immunosorbent assay (ELISA) using the GTI diagnostics kit.

Lupus type inhibitor was not detected, and fibrinogen and all other measured factor levels were normal. Other lab testing revealed: Hemoglobin 75 g/L, Platelets 110×10^9 , creatinine 139 μ mol/L, ANA-, RF-, Hep B and Hep C negative, cryoglobulin and agglutinin testing negative. Based on these investigations, the patient was diagnosed with Acquired von Willebrand syndrome (AVWS). No coagulation factor replacement was required and desmopressin (DDAVP) challenge test demonstrated a good increase in von Willebrand factor and factor VIII levels, without rapid clearance (Factor levels were measured at 30 mins, 1 and 4 hours) (**Table 1**). The patient was treated with prednisone at

Table 1. VWF, VWFpp, and VWFpp:Ag at diagnosis, during DDAVP testing, and in remission.

Coagulation Paramater	Diagnosis	30 min post DDAVP	1 hour post DDAVP	4 hour post DDAVP	Remission
PTT (sec)	45.5	37.1	34.9	35.5	
VWF:Act (GP1b) (IU/dL)	12	54	80	114	
VWF:Ag (IU/dL)	31	66	83	108	
FVIII:C (IU/dL)	14	89	107	115	
GTI VWF:Ag (IU/dL)	18	53			155
GTI VWFpp (IU/dL)	140	281			143
GTI VWFpp:Ag (normal 0.5-2.0)	7.7	5.3			0.9

1mg/Kg with slow dose tapering. No further bleeding has been reported and normalization of von Willebrand factor levels is maintained at 12 months. (Figure 1).

Discussion. Acquired von Willebrand syndrome (AVWS) is a rare hemorrhagic disorder that usually occurs in patients with no previous personal or family history of bleeding.⁷ According to the ISTH registry, 48% and 15% of 186 AVWS cases that qualified for the registry were associated with lymphoproliferative and myeloproliferative disorders.⁸ Among lymphoproliferative disorders AVWS is most commonly associated with Monoclonal Gammopathy of Undetermined Significance (MGUS) in up to 23% of cases.⁹ In

our patient, the pathogenic aetiology of underlying AVWS seemed to be increased clearance of FVIII-VWF complex due to non-neutralizing autoantibodies to VWF given the lack of inhibitory effect on normal plasma on VWF:Act and FVIII:C mixing studies (37 C x 2 hours of incubation). Our patient demonstrated a decrease VWF Ag:Act ratio (0.45), similar to type 2 von Willebrand Disease (VWD) and loss of high and intermediate molecular weight (HMW) multimers, which has been described in aVWS.⁸ (Figure 2) VWFpp levels and VWFpp:Ag ratio were measured and demonstrated increased ratio at diagnosis (7.7, normal range 0.5-2.0) and normal ratio (0.9) in remission suggesting increase clearance of VWF had a role in AVWS for our

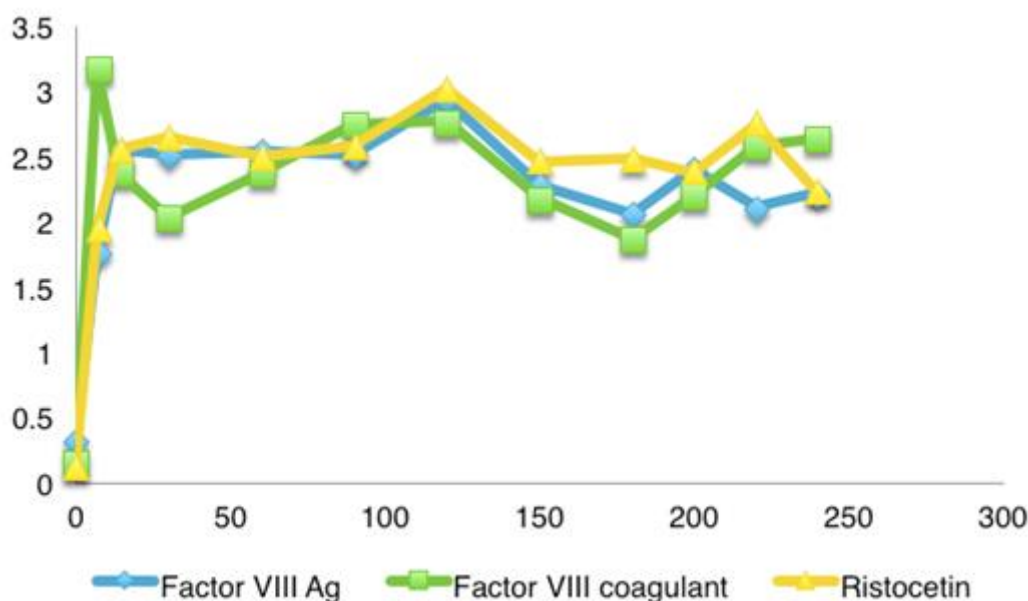


Figure 1. Levels of von Willebrand factor VIII Ag and Ristocetin Cofactor activity. (In the X axis, days from episode of bleeding is shown, while in the Y axis levels in U/mL are recorded).

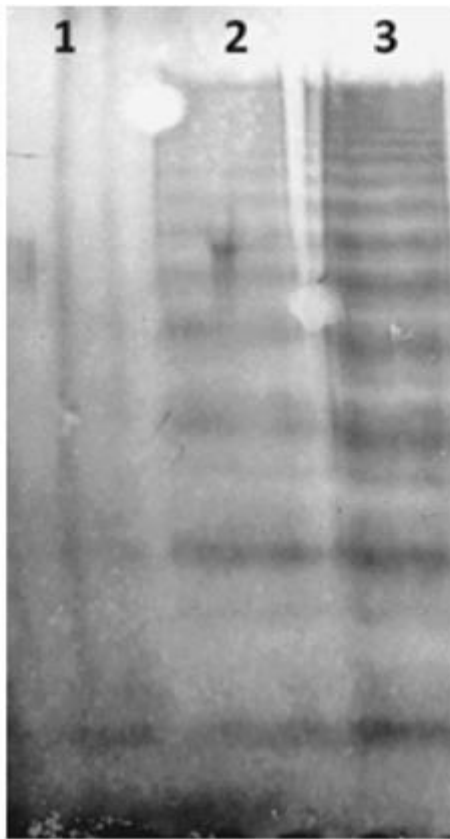

Figure 2. Multimer gel image demonstrated the presence of high molecular weight multimers.

patient. Interestingly, DDAVP was able to stimulate enough secretion of VWF from endothelial Weibel-Palade bodies to overcome the clearance of VWF by the autoantibody, resulting in normalization of VWF:Ag and VWF:Act levels, and reappearance of HMW multimers. The decrease (but still abnormal) VWFpp:Ag ratio (5.3) also reflects the increased secretion stimulated by DDAVP relative to clearance that remained constant. VWFpp is cleaved in the trans-Golgi but remains stored together with mature VWF in platelet α -granules and endothelial cell Weibel-Palade bodies in equimolar amounts. After release, VWFpp dissociates from the mature VWF subunit, circulates with a steady-state half-life, and serves as a marker of VWF secretion.¹⁰ A high VWF:pp/Ag ratio has been proposed by Scott et al.,¹¹ as a simple method to distinguish AVWS due to decreased VWF synthesis from that due to increased clearance. Federici et al.⁸ characterized in their paper some differences in AVWS caused by IgG-MGUS versus IgM MGUS. Although the paper reported on only 8 IgG-MGUS and 2 IgM MGUS, they reported a higher vWF:pp/Ag compared to controls in IgG MGUS but not in IgM MGUS. In addition, a normal multimeric pattern was seen in the IgG MGUS cases but

selective loss of large and intermediate multimers in the IgM-MGUS cases.¹² Our case of IgM MGUS associated AVWS differs in that high VWFpp:Ag was seen, although the loss of high and intermediate molecular weight multimers is similar to that reported by Federici et al.⁸

The treatment goals in AVWS are to control acute bleeds, to prevent bleeding in high-risk situations, and to obtain long-term remission. In this case, DDAVP was able to stimulate enough endogenous secretion of VWF to overcome the clearance caused by the anti-VWF antibody, and maintain normal VWF levels at 1 and 4 hours following DDAVP administration. In other cases of AVWS, DDAVP is often ineffective for treatment as the anti-VWF antibody is either neutralizing, or the clearance of VWF:Ag by the anti-VWF antibody is much greater than the amount of endogenous VWF:Ag that can be secreted by Weibel-Palade bodies. However, in our case, the anti-VWF antibody is non-neutralizing and clearance by this antibody is not so rapid such that the DDAVP-stimulated release of endogenous VWF can overcome the anti-VWF antibody-mediated clearance. This is evidenced by the increased VWF levels following DDAVP stimulation and the decreased VWFpp:Ag ratio.

Bleeding and bruising are common in immunoglobulin light chain (AL) amyloidosis and can occur through a number of mechanisms, thus AVWS is not often considered when bleeding symptoms occur. Kos et al.,¹³ recently reported a small series of cases where the association of active AL amyloid and the appearance of AVWS was noted. In our current report, in contrast, this association was observed even in the setting of complete haematological response. To our knowledge this is the first case report of post-transplant IgM lambda secondary MGUS treated with high dose prednisone. However, a previous report by Lazarchick et al.,¹⁴ described a 41 y/o male who after undergoing allogeneic bone marrow transplantation for the treatment of acute myeloid leukemia was admitted with worsening chronic GVHD and subsequently was found to have markedly reduction of von Willebrand factor antigen consistent with a diagnosis of AVWS. Our current report also illustrates the emerging complications for patients with AL amyloidosis receiving bortezomib-containing regimens prior to stem cell transplantation. Further data in this regard is needed to better understand the

mechanisms by which these complications occur and how to minimize the morbidity related to these events.

Acknowledgements. We would like to

acknowledge Paula James' laboratory in Kingston, ON for performing VWF propeptide assays, and Gary Sinclair's Molecular hematology laboratory for performing the multimer analysis.

References:

1. Rosenzweig M, Giral S, Landau H. Light-chain amyloidosis: SCT, novel agents and beyond. *Bone Marrow Transplant.* 2013;48(8):1022-1027. <https://doi.org/10.1038/bmt.2012.199> PMID:23103675
2. Jimenez-Zepeda VH, Franke N, Reece DE, et al. Autologous stem cell transplant is an effective therapy for carefully selected patients with AL amyloidosis: experience of a single institution. *Br J Haematol.* 2014;164(5):722-728. <https://doi.org/10.1111/bjh.12673> PMID:24266428
3. Roy V. Autologous stem cell transplant for AL amyloidosis. *Bone Marrow Res.* 2012;2012:238961. <https://doi.org/10.1155/2012/238961> PMID:22675637 PMCID:PMC3361989
4. Comenzo RL. Amyloidosis. *Curr Treat Options Oncol.* 2006;7(3):225-236. <https://doi.org/10.1007/s11864-006-0015-8> PMID:16615878
5. Dispenzieri A, Buadi F, Kumar SK, et al. Treatment of Immunoglobulin Light Chain Amyloidosis: Mayo Stratification of Myeloma and Risk-Adapted Therapy (mSMART) Consensus Statement. *Mayo Clin Proc.* 2015;90(8):1054-1081. <https://doi.org/10.1016/j.mayocp.2015.06.009> PMID:26250727
6. Santhorawala V, Brauneis D, Shelton AC, et al. Induction Therapy with Bortezomib Followed by Bortezomib-High Dose Melphalan and Stem Cell Transplantation for Light Chain Amyloidosis: Results of a Prospective Clinical Trial. *Biol Blood Marrow Transplant.* 2015;21(8):1445-1451. <https://doi.org/10.1016/j.bbmt.2015.04.001> PMID:25858810
7. Voisin S, Hamidou M, Lefrancois A, Sigaud M, Mahe B, Trossaert M. Acquired von Willebrand syndrome associated with monoclonal gammopathy: a single-center study of 36 patients. *Medicine (Baltimore).* 2011;90(6):404-411. <https://doi.org/10.1097/MD.0b013e3182397166>
8. Federici AB RJ, Bucciarelli P, Budde U, van Genderen PJ, Mohri H, Meyer D, Rodeghiero F, Sadler JE. Acquired von Willebrand syndrome: data from an international registry. *Thromb Haemost.* 2000;84(2):345-349. PMID:10959711
9. Franchini M, Lippi G. Acquired von Willebrand syndrome: an update. *Am J Hematol.* 2007;82(5):368-375. <https://doi.org/10.1002/ajh.20830> PMID:17133419
10. Lee A, Sinclair G, Valentine K, James P, Poon MC. Acquired von Willebrand syndrome: von Willebrand factor propeptide to von Willebrand factor antigen ratio predicts remission status. *Blood.* 2014;124(5):e1-3. <https://doi.org/10.1182/blood-2014-02-557132> PMID:24951428 PMCID:PMC4729537
11. Scott JPV, E. A.; Schroeder, T.; Foster, P. A.; Gill, J. C.; Montgomery, R. R. The Von Willebrand factor propeptide, Von Willebrand antigen II, distinguishes acquired Von Willebrand syndrome due to decreased synthesis of Von Willebrand factor from AvWS due to increased clearance of vWF. *Blood.* 1995;86(10 (Suppl 1)).
12. Federici AB, Stabile F, Castaman G, Canciani MT, Mannucci PM. Treatment of acquired von Willebrand syndrome in patients with monoclonal gammopathy of uncertain significance: comparison of three different therapeutic approaches. *Blood.* 1998;92(8):2707-2711. PMID:9763553
13. Kos CA, Ward JE, Malek K, et al. Association of acquired von Willebrand syndrome with AL amyloidosis. *Am J Hematol.* 2007;82(5):363-367. <https://doi.org/10.1002/ajh.20829> PMID:17205535
14. Lazarchick J, Green C. Acquired von Willebrand's disease following bone marrow transplantation. *Ann Clin Lab Sci.* 1994;24(3):211-215. PMID:8048792