



Original Articles

**Liver Iron Content (LIC) in Adults with Sickle Cell Disease (SCD): Correlation with Serum Ferritin and Liver Enzymes Concentrations in Transfusion Dependent (TD-SCD) and Non-Transfusion Dependent (NT-SCD) Patients**

Mohamed Yassin<sup>1</sup>, Ashraf Soliman<sup>2</sup>, Vincenzo De Sanctis<sup>3</sup>, Abdelqadir Nashwan<sup>4</sup>, Sandra Abusamaan<sup>5</sup>, Abbas Moustafa<sup>5</sup>, Samah Kohla<sup>6</sup> and Dina Soliman<sup>6</sup>

<sup>1</sup> Department of Hematology, Hamad Medical Center, Doha.

<sup>2</sup> Department of Pediatric, University of Alexandria, Egypt.

<sup>3</sup> Department of Pediatric and Adolescent Outpatient Clinic, Quisisana Hospital, Ferrara, Italy.

<sup>4</sup> Department of Nursing HMC, Doha, Qatar.

<sup>5</sup> Department of Radiology, Doha, Qatar.

<sup>6</sup> Department of Laboratory Medicine, Doha, Qatar.

**Competing interests:** The authors have declared that no competing interests exist.

**Abstract. Introduction:** Sickle cell disease (SCD) is one of the leading causes of morbidity and mortality worldwide, causing damage and dysfunction in multiple organs. The complications of this disease are numerous, affect every organ and/or tissue in the body and vary considerably among patients over the time challenging its management.

**The aim of our study:** To determine the iron status of 17 patients with non-transfusion-dependent sickle cell disease ( NT-SCD) patients and six patients with transfusion dependent sickle cell disease (TD- SCD) using both serum ferritin level (SF) and Ferriscan® evaluation of liver iron content (LIC). We correlated the values of LIC with SF levels and some hepatic enzymes (alanine transaminase-ALT, aspartate aminotransferase -AST, alkaline phosphatase -ALP and albumin).

**Results:** 17 adults with NT-SCD (n = 17, age: 32±15 years) were studied. Seven of NT-SCD had SF > 500 µg/L, 4 out of the seven had high liver iron measured by FerriScan® (> 30 mg/g/ tissue dry weight - dw). Two patients had high LIC despite a concomitant SF concentration < 500 µg/L. Two patients had high SF (1.117 µg/L and 675 µg/L) while their LIC was normal (< 30 mg/g/dw). Five patients had elevated ALT and/or AST) concentrations. In TD-SCD (n = 6, age = 25 ± 11 years), 2 patients had SF <500 µg/L, one of them had high LIC (127 mg/g/DW). Liver enzymes were high in two patients. SF concentration correlated significantly with LIC (r = 0.85, p < 0.001). Neither SF level nor LIC was correlated significantly with hepatic enzyme levels.

**Conclusions:** A significant number of our patients with NT-SCD had high LIC, high SF and elevated liver enzymes (ALT and AST). Despite some limitations of our study, due to the limited number of NT-SCD patients, these findings have important clinical implications. Therefore, we recommend measuring SF and LIC in NT-SCD patients to apply preventive measures with iron chelation therapy in patients with high LIC.

**Keywords:** Sickle Cell Disease; Iron Overload; Ferriscan; Ferritin; Liver Iron Content.

**Citation:** Yassin M., Soliman A., De Sanctis V., Nashwan A., Abusamaan S., Moustafa A., Kohla S., Soliman D. Liver iron content (LIC) in adults with sickle cell disease (SCD): correlation with serum ferritin and liver enzymes concentrations in transfusion dependent (TD-SCD) and non-transfusion dependent (NT-SCD) patients. *Mediterr J Hematol Infect Dis* 2017, 9(1): e2017037, DOI: <http://dx.doi.org/10.4084/MJHD.2017.037>

Published: June 20, 2017

Received: December 21, 2016

Accepted: May 18, 2017

This is an Open Access article distributed under the terms of the Creative Commons Attribution License (<https://creativecommons.org/licenses/by-nc/4.0/>),



**Introduction.** Some haemoglobinopathies, such as thalassaemia major (TM), are severe enough to require life-long blood transfusions whereas patients with non-transfusion-dependant thalassaemia (NT-T) and sickle cell disease (SCD) will need either intermittent, regular or no transfusions, dependent on disease severity and disease-related complications. Regular blood transfusions result in the gradual accumulation of iron, initially in the liver, and then throughout the body including the heart and endocrine organs. In contrast, subjects with non-transfusion-dependent sickle cell disease (NT-SCD) may be relatively protected from iron-mediated liver, cardiac and endocrine gland toxicity.<sup>1-3</sup>

Making a clinical diagnosis of iron overload is difficult because patients do not usually develop clinical symptoms until the advanced stages of the disease.

The biochemical markers of the iron metabolism disorders include an elevated concentration of iron and serum ferritin (SF) and transferrin saturation in plasma. However, these parameters are not always specific for body iron load.<sup>4</sup> Furthermore, SF can be unreliable in SCD due to the inflammatory nature of the condition, even in the steady state.<sup>5</sup>

In a cross-sectional study of 27 children ( $10.9 \pm 3.3$  years) with SCD who had received chronic transfusion therapy without chelation, transfusion volume provided more insight on liver iron content (LIC) than serum iron markers.<sup>6</sup>

In another study of 20 patients with SCD undergoing chronic transfusion therapy with iron chelation, LIC showed a positive correlation with the duration of transfusion and liver fibrosis but not with serum markers.<sup>7</sup>

The gold standard for assessing liver iron stores, in the absence of cirrhosis, is the LIC, determined by liver biopsy and quantitation with atomic absorption spectrophotometry. The normal LIC is between 0.4 and 2.2 mg/g of dry liver weight. Based on data from hereditary hemochromatosis,  $< 7$  mg/g is not associated with obvious hepatic pathology while  $>15$  mg/g is consistently associated with liver fibrosis.<sup>8</sup>

The use of biopsy-measured LIC is limited by the small but finite risk of complications of liver

biopsy, lack of reproducibility of quantitative assays, and sampling error.<sup>9</sup>

Magnetic resonance imaging (MRI) is a non-invasive method that detects iron overload and allows to monitor treatment after diagnosis, avoiding repeated biopsies. In fact, iron ions have the paramagnetic properties, and its accumulation in the tissues causes local distortion in the magnetic fields, with a consequent loss of signal intensity in the affected organs that is proportional to the amount of iron deposited.<sup>10</sup> A standardized and validated MRI method is now registered in Europe and the United States (Ferriscan®), with a reproducible relationship between the value (R2) by MRI and LIC by biopsy over a clinically useful range in which locally acquired data are analyzed at a central facility. This is potentially available in any hospital with an MRI scanner and with minimal training of local staff.<sup>10,11</sup>

SCD patients, despite their transfusion-independence, can accumulate iron due to increased intestinal absorption. Since the guidelines for the use of chelation therapy in SCD with iron overload are based on the same principles as those for TM to avoid serious clinical sequelae,<sup>12</sup> we measured LIC using FerriScan® in two groups of SCD patients with transfusion dependent (TD-SCD) and non-transfusion dependent (NT-SCD) in order to assess which parameters most effectively predicted iron loading in the liver.

**Patients and Methods.** Eleven adult patients with NT-SCD who did not receive any blood transfusion for at least five years and 6 NT-SCD patients with a clinical history of occasional blood transfusions (less than six units of blood), for sickling episodes during early childhood period, were studied.

Twenty-six percent of patients were female. None of them had been splenectomized. Their hemoglobin (Hb) level varied from 7 to 10.5 g/dl. Hepatitis screening for HBV, HCV, and HIV was negative in all patients. Patients were tested for hemochromatosis genes C282Y, and H63 D and both mutations were negative. Our ND-SCD were slightly older than TD-SCD patients.

Six patients with TD-SCD (on regular blood transfusion and iron chelation) were studied as controls. They were all on top-up transfusion, and none of them was on transfusion-exchange program. They used to be chelated with oral deferasirox (30 mg/kg/day) for the past four years and previously received subcutaneous daily desferrioxamine therapy. Their compliance to chelation before oral therapy was variable.

An extensive medical history, including transfusion and chelation therapy, and a physical examination was performed for each patient. Their Hb electrophoresis diagnosis of SCD was confirmed. All other hemoglobinopathies were excluded. All SCD patients had a HbSS genotype. Lab investigations included measurement of their serum concentrations of iron, total iron binding capacity (TIBC), serum ferritin, alkaline phosphatase (ALP), alanine transferase (ALT), aspartate transferase (AST) and albumin concentrations. Liver iron content (LIC) was measured using Ferriscan®.<sup>10,11</sup>

SF was measured by immune-enzymatic and electrochemiluminescence immunoassays. The manufacturer's normal reference range values were 30-350 µg/L in males and 15-150 µg/L in females.

LIC values were expressed as mg/g dry weight (DW). LIC (mg Fe/gr dw) were classified into: normal (LIC <3); mild (LIC > 3 and < 7), moderate (LIC > 7 and < 14) and severe overload (LIC > 14).<sup>13</sup>

All SCD patients had cardiac MRI T2\* for evaluation of their cardiac iron overload using a 1.5 T scanner (GE Signa/Excite HD, Milwaukee, WI, USA). A conservative cut-off value of heart T2\* > 20 ms was considered normal.<sup>14</sup>

Ethical approval for the study was obtained by Ethical Committee of Hamad General Hospital which were in accordance, by the Declaration of Helsinki (<http://www.wma.net>). All procedures were carried out with the adequate understanding and consent of patients.

Pearson's and Spearman's correlation tests were used to studying correlations between variables with parametric and non-parametric distributions respectively.  $p < 0.05$  was considered significant.

**Results.** 17 adults with NT-SCD ( $n = 17$ , age:  $32 \pm 15$  years) were studied. Seven of NT-SCD had SF > 500 µg/L. Four out of 7 had high LIC measured by Ferriscan® (> 30 mg/g/DW). Two of them had history of receiving two blood

transfusions during their childhood. Two NT-SCD patients had high LIC despite a concomitant SF < 500 µg/L. Two patients had high SF (1.117 µg/L and 675 µg/L) while their LIC was normal (< 30 mg/g/DW). Five patients had elevated ALT and/or AST concentrations. Out of the 17 patients with NT-SCD, 1 had mild (LIC > 3 and < 7), 13 had moderate (LIC > 7 and < 14) and 3 had severe iron overload (LIC > 14).

The NT-SCD group consisted of 11 non-transfused, and six occasionally transfused patients. There was no significant difference between the two groups since the occasional transfusion group received less than six units of blood which appears to be insufficient in producing a significant iron overload.

The six patients with TD-SCD (age:  $25 \pm 11$  years), on regular blood transfusion and iron chelation with deferasirox (30 mg/g body weight, Exjade®) had SF < 500 µg/L, and one had increased LIC (127 mg/g/DW). Liver enzymes were high in 2 patients.

SF concentrations and LIC were significantly higher in TD-SCD versus NT-SCD patients (**Table 1**).

In all studied patients (NT-SCD and TD-SCD) the SF concentrations were correlated significantly with LIC, measured by Ferriscan ( $r = 0.85$ ,  $p < 0.001$ ) (**Figure 1**). LIC was also significantly correlated with ALT concentrations ( $r = 0.464$ ,  $p = 0.02$ ) SF levels did not correlate significantly with serum ALT, AST or ALP. Serum iron concentration and TIBC did not correlate with SF, LIC or ALT and AST concentrations.

In the TD-SCD patient group, neither LIC nor serum ferritin was correlated significantly with total elemental iron received by transfusions ( $r = 0.2$  and  $0.02$ ;  $p > 0.05$ ).

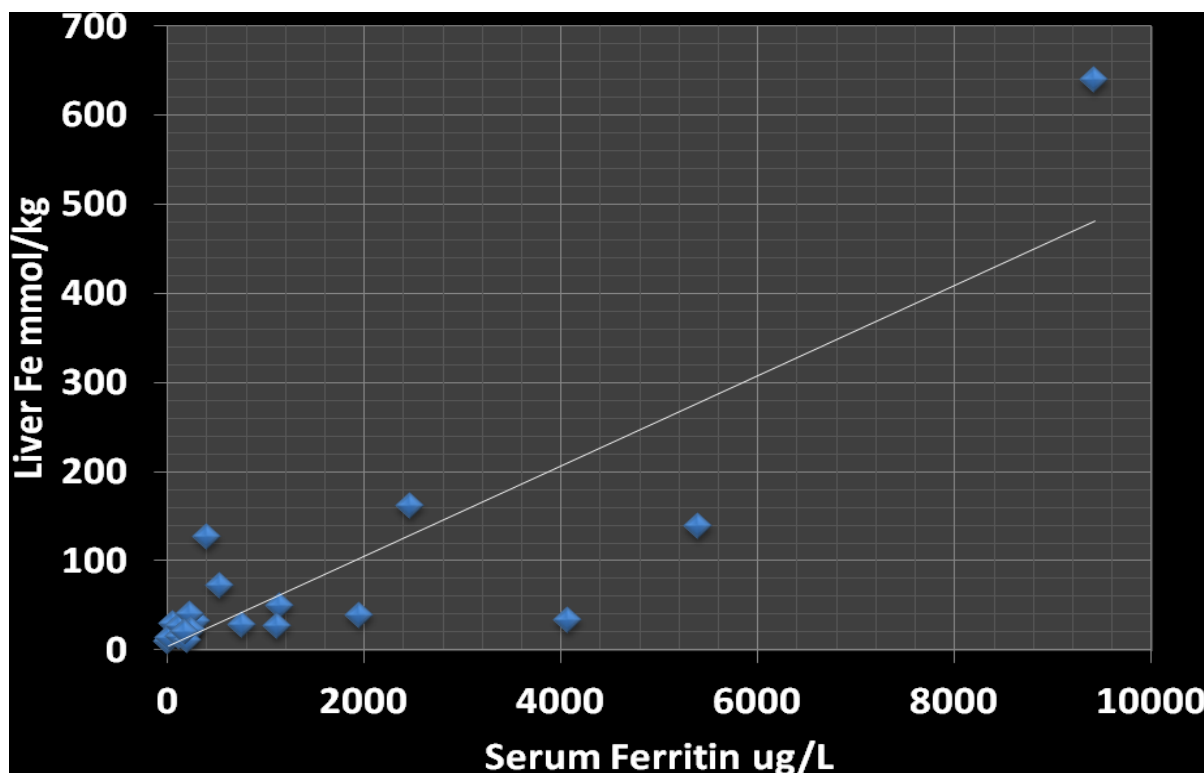
None of the NT-SCD or TD-SCD patients had significant cardiac iron overload.

Multiple regression analysis including all studied factors (serum iron, iron binding capacity, ALT, AST, albumin) revealed that LIC was the only factor contributing significantly to serum ferritin level (coefficient = 14.5;  $t$  stat = 5.7;  $p = 0.00003$ )

**Discussion.** Sickle cell disease is an important cause of morbidity and mortality worldwide, causing damage and dysfunction in multiple organs. The complications of this disease are

**Table 1.** Biochemical and liver iron data of SCD patients: TD-SDC versus NT-SCD.

NTD-SCD										
Age	serum Fe	TIBC	Ferritin	liver iron	ALT	AST	ALP	Albumin		
yr	umol/L	umol/L	ug/L	mg/g	U/L	U/L	U/L	g/L		
44.0	5.0	60.0	12.0	0.5	7.0	14.0	46.0	38.0		
27.0	25.0	51.0	1138.0	2.7	13.0	16.0	135.0	41.0		
28.0	13.0	44.0	1117.0	1.5	20.0	41.0	155.0	42.0		
21.0	22.0	52.0	213.0	1.0	55.0	50.0	65.0	47.0		
37.0	72.0	74.0	224.0	1.4	16.0	34.0	73.0	48.0		
16.0	25.0	57.0	63.0	1.6	56.0	89.0	71.0	46.0		
60.0	9.0	49.0	25.0	0.7	20.0	23.0	136.0	38.0		
17.0	20.0	60.0	299.0	1.8	18.0	28.0	128.0	47.0		
46.0	16.0	47.0	531.0	4.0	17.0	23.0	41.0	47.0		
40.0	28.0	58.0	120.0	1.5	15.0	22.0	68.0	46.0		
19.0	26.0	61.0	237.0	2.3	29.0	57.0	80.0	49.0		
25.0	23.9	55.0	765.0	1.5	12.0	29.0	88.0	43.0		
43.0	46.0	59.0	1954.0	2.2	12.0	49.0	82.0	33.0		
28.0	20.0	38.0	118.0	0.9	21.9	37.0	92.0	48.0		
59.0	16.0	56.0	245.0	1.2	26.0	42.0	114.0	43.0		
8.0	16.6	43.0	5395.0	7.8	46.0	52.0	119.0	42.0		
27.0	22.5	56.0	205.0	0.6	16.0	22.0	80.0	47.0		
Mean	32.1	23.7	55.7	744.8	2.0	22.3	36.5	90.7	43.8	
SD	14.9	17.7	8.4	405.7	1.7	15.6	20.8	40.0	4.4	
TDSDS										
										Total Fe recived by transfusion
18.0	33.0	51.0	9420.0	36.0	54.0	40.0	117.0	43.0		86400.0
14.0	14.5	38.0	184.0	1.1	9.0	22.0	90.0	44.0		67200.0
42.0	29.0	28.0	3320.0	9.0	77.0	59.0	391.0	47.0		201600.0
22.0	24.0	41.0	400.0	7.2	14.0	33.0	73.0	46.0		105600.0
29.0	26.0	37.0	4074.0	1.8	11.0	21.0	158.0	44.0		139200.0
25.5	24.0	40.0	2474.0	9.0						119000.0
Mean	25.0	25.2	3310.4	11.0	33.0	35.0	165.8	44.8		120000.0
SD	11.0	9.6	11.5	3770.1	14.4	30.8	15.6	129.9	1.6	52800.0



**Figure 1.** Correlation between Liver iron by ferri-scan and serum ferritin concentration ( $r = 0.845$ ,  $p < 0.001$ )

numerous, affect every organ and/or tissue in the body and vary considerably among patients over the time challenging its management. Greater focus on the long-term hepatic consequences of iron overload is recommended in SCD.

Our study confirms an increased (LIC >30 mg/g dry tissue) and high SF in a considerable number of patients with NT-SCD with no or insignificant previous blood transfusions. Some of the NT-SCD had a high LIC despite an SF < 500 µg/L.

In SCD the liver can be affected by several complications due to the disease itself and its treatment. Hepatic siderosis is a growing area of concern and research.<sup>15</sup> As red cell transfusions become routine for more indications, the inevitable result is the accumulation of liver iron. Over many years, hepatic dysfunction, insufficiency, fibrosis, and cirrhosis may lead to morbidity. Chelation with deferoxamine, deferasirox, or deferiprone has been used to reduce total body iron.<sup>15,16</sup>

Scarce information is available in the literature regarding patients receiving sporadically blood transfusions. Drasar et al.<sup>17</sup> observed that even sporadically transfused patients can become heavily iron overloaded, on par with those on transfusion programs.

Our findings confirm these data and indicate that some adults with NT-SCD have a considerable hepatic iron overload that may adversely affect their hepatic function. The positive correlation between LIC and serum concentration of ALT support the concept of the deleterious effect of iron overload on hepatocytes.<sup>3,17,18</sup> It should be mentioned, however, that our NT-SCD were slightly older than TD-SCD patients.

In our patients (NT-SCD and TD-SCD), SF serum ferritin levels were correlated significantly with LIC measured by Ferriscan validating the use of SF as a screening test for assessing iron overload in SCD patients (Figure 1). However, the finding of some cases with high LIC despite SF < 500 µg/L necessitates measuring LIC with these

non-invasive methods when hepatic symptoms or signs (e.g, hepatomegaly, liver tenderness, elevated hepatic enzymes appear, even in the absence of high serum ferritin).

Excess iron may result from the parenteral administration (blood transfusion) or increased intestinal absorption. The iron absorbed by the small intestine (duodenum and proximal jejunum) binds to transferrin—a transport protein in the blood. Once iron is bound to transferrin, it is selectively deposited in hepatocytes, red blood cells or, to a lesser extent, in other iron containing tissues, like muscle.<sup>18,19</sup> This explains significant iron overload in TD-SCD especially those with poor compliance to iron chelation. However, in patients with NT-SCD iron overload appears to be primary due chronic hemolysis.

Ferriscan is one of the available systems to evaluate LIC. MRI is noninvasive and has been shown to provide accurate results compared to the gold standard. It is widely available across the world and several different models for calculating LIC using MRI, both T2 relaxometry and signal intensity ratio (SIR) methods, are being used with satisfactory results.<sup>20</sup>

Our data suggest that monitoring for iron overload and its complications, using non-invasive methods, is important, even though these are less frequent in SCD compared to thalassaemia major patients (TM). Chelation treatment could be reconsidered earlier in this cohort of patients with high LIC. Guidelines for starting chelation therapy in SCD patients are based on the same principles as those for TM (SF is > 1000 µg/L or LIC is > 7 mg/g dry weight or > 20 top-up units of transfusion).<sup>21</sup>

**Conclusions.** In both NT- SCD and TD- SCD monitoring liver iron status by measuring SF and LIC, using Ferriscan® method, can diagnose early hepatic iron overload. This helps to decide about starting and tailoring iron chelation accordingly to reduce risk of developing hepatopathy in these patients.

## References:

1. Porter J , Garbowski M. Consequences and management of iron overload in sickle cell disease. ASH Education Book December 6, 2013 vol. 2013 no. 1 447-456. <http://asheducationbook.hematologylibrary.org/content/2013/1/44/7.full>
2. Mohanty D, Mukherjee MB, Colah RB, Wadia M, Ghosh K, Chottray GP, Jain D, Italia Y, Ashokan K, Kaul R, Shukla DK, Muthuswamy V. Iron deficiency anaemia in sickle cell disorders in India. Indian J Med Res 2008; 127:366-369. PMID:18577791
3. Walter PB, Harmatz P, Vichinsky E. Iron metabolism and iron chelation in sickle cell disease. Acta Haematol 2009;122:174-183. <https://doi.org/10.1159/000243802> PMID:19907155
4. Nielsen P, Engelhardt R, Düllmann J, Fischer R. Non-Invasive Liver Iron Quantification by SQUID-Biosusceptometry and



- Serum Ferritin Iron as New Diagnostic Parameters in Hereditary Hemochromatosis. *Blood Cells Mol Dis* 2002;29:451-458. <https://doi.org/10.1006/bcmd.2002.0583> PMID:12547235
5. Adamkiewicz TV, Abboud MR, Paley C, Olivieri N, Kirby-Allen M, Vichinsky E, Casella JF, Alvarez OA, Barredo JC, Lee MT, Iyer RV, Kutlar A, McKie KM, McKie V, Odo N, Gee B, Kwiatkowski JL, Woods GM, Coates T, Wang W, Adams RJ. Serum ferritin level changes in children with sickle cell disease on chronic blood transfusion are nonlinear and are associated with iron load and liver injury. *Blood* 2009;114:4632-4638. <https://doi.org/10.1182/blood-2009-02-203323> PMID:19721013 PMID:PMC2780299
  6. Brown K, Subramony C, May W, Megason G, Liu H, Bishop P, Walker T, Nowicki MJ. Hepatic iron overload in children with sickle cell anemia on chronic transfusion therapy. *J Pediatr Hematol Oncol* 2009;31:309-312. <https://doi.org/10.1097/MPH.0b013e3181a1e143> PMID:19415007
  7. Harmatz P, Butensky E, Quirolo K, Williams R, Ferrell L, Moyer T, Golden D, Neumayr L, Vichinsky E. Severity of iron overload in patients with sickle cell disease receiving chronic red blood cell transfusion therapy. *Blood* 2000;96:76-79. PMID:10891433
  8. Bassett ML, Halliday JW, Powell LW. Value of hepatic iron measurements in early hemochromatosis and determination of the critical iron level associated with fibrosis. *Hepatology* 1986;6:24-29. <https://doi.org/10.1002/hep.1840060106> PMID:3943787
  9. Angelucci E, Baronciani D, Lucarelli G, Baldassari M, Galimberti M, Giardini C, Martinelli F, Polchi P, Polizzi V, Ripalti M. Needle liver biopsy in thalassaemia: analyses of diagnostic accuracy and safety in 1184 consecutive biopsies. *Br J Haematol* 1995;89:757-761. <https://doi.org/10.1111/j.1365-2141.1995.tb08412.x> PMID:7772512
  10. St Pierre TG, Clark PR, Chua-Anusorn W, Fleming AJ, Jeffrey GP, Olynyk JK, Pootrakul P, Robins E, Lindeman R. Noninvasive measurement and imaging of liver iron concentrations using proton magnetic resonance. *Blood* 2005;105:855-861. <https://doi.org/10.1182/blood-2004-01-0177> PMID:15256427
  11. Hankins JS, McCarville MB, Loeffler RB, Smeltzer MP, Onciu M, Hoffer FA, Li CS, Wang WC, Ware RE, Hillenbrand CM. R2\* magnetic resonance imaging of the liver in patients with iron overload. *Blood* 2009;113:4853-4855. <https://doi.org/10.1182/blood-2008-12-191643> PMID:1926477 PMID:PMC2686136
  12. Inati A. Recent advances in improving the management of sickle cell disease. *Blood Rev* 2009;23 (Suppl 1):S9-13. [https://doi.org/10.1016/S0268-960X\(09\)70004-9](https://doi.org/10.1016/S0268-960X(09)70004-9)
  13. Casale M, Meloni A, Filosa A, Cuccia L, Caruso V, Palazzi G, Gamberini MR, Pitrolo L, Putti MC, D'Ascola DG, Casini T, Quarta A, Maggio A, Neri MG, Positano V, Salvatori C, Toia P, Valeri G, Midiri M, Pepe A. Multiparametric Cardiac Magnetic Resonance Survey in Children With Thalassemia Major: A Multicenter Study. *Circ Cardiovasc Imaging*. 2015 Aug;8(8):e003230. <https://doi.org/10.1161/CIRCIMAGING.115.003230> PMID:26253625
  14. Positano V, Pepe A, Santarelli MF, Scattini B, De Marchi D, Ramazzotti A, Forni G, Borgna-Pignatti C, Lai ME, Midiri M, Maggio A, Lombardi M, Landini L. Standardized T2\* map of normal human heart in vivo to correct T2\* segmental artefacts. *NMR Biomed* 2007;20:578-590. <https://doi.org/10.1002/nbm.1121> PMID:17205488
  15. Vichinsky E, Butensky E, Fung E, Hudes M, Theil E, Ferrell L, Williams R, Louie L, Lee PD, Harmatz P. Comparison of organ dysfunction in transfused patients with SCD or beta thalassemia. *Am J Hematol*. 2005;80:70-74. <https://doi.org/10.1002/ajh.20402> PMID:16138345
  16. Ballas SK, Kesen MR, Goldberg MF, Luty GA, Dampier C, Osunkwo I, Wang WC, Hoppe C, Hagar W, Darbari DS, Malik P. Beyond the definitions of the phenotypic complications of sickle cell disease: an update on management. *Scientific World Journal*. 2012; 2012:949535 <https://doi.org/10.1100/2012/949535> PMID:22924029 PMID:PMC3415156
  17. Drasar E, Vasavda N, Igbneweka N, Awogbade M, Allman M, Thein SL. Serum ferritin and total units transfused for assessing iron overload in adults with sickle cell disease. *Br J Haematol* 2012;157:645-647. <https://doi.org/10.1111/j.1365-2141.2012.09060.x> PMID:22332939
  18. Spina JC, Alvarez del Rivero MA, Kidd C, Pietrani M, Savluky L, García Mónaco RD. Noninvasive assessment of hepatic iron overload in patients with hemochromatosis *Rev Argent Radiol* 2013; 77:139-146.
  19. Lucania G, Vitrano A, Filosa A, Maggio A. Chelation treatment in sickle-cell-anaemia: much ado about nothing? *Br J Haematol*. 2011; 154:545-555. <https://doi.org/10.1111/j.1365-2141.2011.08769.x> PMID:21707578
  20. Alústiza JM, Emparanza JI, Castiella A, Casado A, Garrido A, Aldazábal P, San Vicente M, García N, Asensio AB, Banales J, Salvador E, Moyua A, Arozena X, Zarco M, Jauregui L, Vicente O. Measurement of liver iron concentration by MRI is reproducible. *Biomed Res Int*. 2015;2015:294024. <https://doi.org/10.1155/2015/294024>
  21. Siegelman ES, Mitchell DG, Semelka RC. Abdominal iron deposition: metabolism, MR findings, and clinical importance. *Radiology*. 1996;199:13-22. <https://doi.org/10.1148/radiology.199.1.8633135> PMID:8633135