



Case Reports

Idiopathic Pulmonary Embolism in a case of Severe Family ANKRD26 Thrombocytopenia

Jerome Guison¹, Gilles Blaison¹, Oana Stoica¹, Remy Hurstel², Marie Favier³ and Remy Favier⁴

¹ Service de médecine interne et maladies infectieuses, Centre Haut-Rhinois de compétence des maladies systémiques et auto-immunes rares, Hôpital Pasteur, Hôpitaux civils de Colmar, 39 avenue de la liberté, 68024 COLMAR.

² Laboratoire d'hématologie et d'hémostase, Hôpital Pasteur, Hôpitaux civils de Colmar, 39 avenue de la liberté, 68024 COLMAR.

³ Faculté de médecine, INRA/UMR 1260; 27 boulevard J. Moulin, 13385 MARSEILLE.

⁴ Service d'hématologie biologique, Centre de référence des pathologies plaquettaires, Assistance Publique-Hôpitaux de Paris, Hôpital Armand Trousseau, 26 avenue du Dr Netter, 75012 PARIS.

Competing interests: The authors have declared that no competing interests exist.

Abstract. Venous thrombosis affecting thrombocytopenic patients is challenging. We report the case of a woman affected by deep vein thrombosis and pulmonary embolism in a thrombocytopenic context leading to the discovery of a heterozygous mutation in the gene encoding ankyrin repeat domain 26 (ANKRD26) associated with a heterozygous factor V (FV) Leiden mutation. This woman was diagnosed with lower-limb deep vein thrombosis complicated by pulmonary embolism. Severe thrombocytopenia was observed. The genetic study evidenced a heterozygous FV Leiden mutation. Molecular study sequencing was performed after learning that her family had a history of thrombocytopenia. Previously described heterozygous mutation c-127C>A in the 5'untranslated region (5'UTR) of the ANKRD26 gene was detected in the patient, her aunt, and her grandmother. ANKRD26-related thrombocytopenia and thrombosis are rare. This is, to our knowledge, the first case reported in the medical literature. This mutation should be screened in patients with a family history of thrombocytopenia.

Keywords: Ankyrin repeat domain 26; familial platelet disorder; associated myeloid malignancy; pulmonary embolism; thrombocytopenia.

Citation: Guison J, Blaison G, Stoica O, Hurstel R, Favier M, Favier R: Idiopathic pulmonary embolism in a case of severe family ankrd26 thrombocytopenia. *Mediterr J Hematol Infect Dis* 2017, 9(1): e2017038, DOI: <http://dx.doi.org/10.4084/MJHID.2017.038>

Published: June 16, 2017

Received: February 17, 2017

Accepted: May 15, 2017

This is an Open Access article distributed under the terms of the Creative Commons Attribution License (<https://creativecommons.org/licenses/by-nc/4.0>), which permits unrestricted use, distribution, and reproduction in any medium, provided the original work is properly cited.

Correspondence to: Jérôme Guison, M.D. Service de médecine interne et maladies infectieuses, Centre Haut-Rhinois de compétence des maladies systémiques et auto-immunes rares. Hôpital Pasteur, Hôpitaux civils de Colmar, 39 avenue de la liberté, 68024 COLMAR. Tel: +33 (0) 389124123 - Fax: +33 (0) 389124691. E-mail: jerome.guison@ch-colmar.fr

Case Report. A 20-year-old woman (**Figure 1, III-3**) was admitted to our department after being diagnosed with spontaneous left lower limb deep vein thrombosis (DVT) located in the external iliac vein. She had no recent history of travel, limb surgery, or smoking habits. Her medical background consisted of one episode of infectious pneumopathy (1 year before this case) complicated with pachypleuritis, an upper humeral extremity

fracture, and migraines. No thrombosis episodes were known in the family. Her medication consisted of a combined oral contraceptive pill taken for two years (levonorgestrel 0.150 mg/ethinyl estradiol 0.030 mg). Except for an edematous limb, the patient was asymptomatic. Laboratory investigations (Sysmex XE-5000 and XE-2100) revealed the following: hemoglobin, 13.4 g/dL; microcytic red blood cells (mean

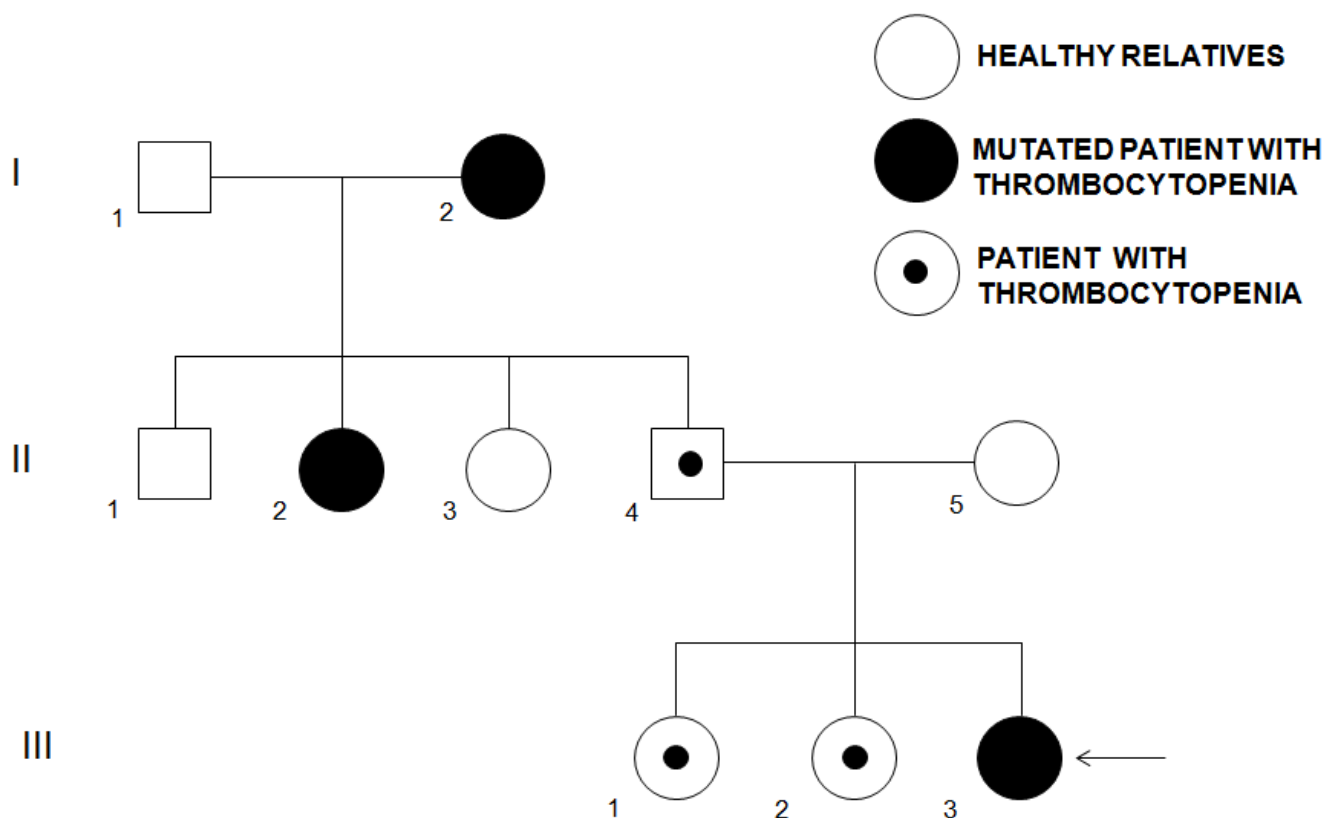
corpuscular volume, MCV), $76\mu^3$; increased white blood cell (WBC) count, 15.6 G/L; and low platelet count, 35 G/L. Mean platelet volume (MPV) was normal (11 fL; laboratory rates: 7.2–11.1 fL). Prothrombin time was 12.6 s (P/C ratio, 1.14) and activated partial thromboplastin time, 28.5 s (P/C ratio, 0.91). The iron stock was normal, as were protein electrophoresis, antibodies, and other biological parameters. Arterial gasometry showed a normal pH (7.43) and a shunt effect. Electrocardiogram and transthoracic echocardiography (left ventricular ejection fraction, 67%) were normal. Functional respiratory investigations were slightly modified. Bone marrow study was not performed. We retrieved the patient's hematological parameters performed one year before during the infectious episode: platelet count was then low at 134 G/L with normal MPV (10.1 fL), red blood cells were microcytic (MCV: $79.8\mu^3$) with anemia (hemoglobin, 9.5 g/dL). WBC count was increased to 20 G/L with a high level of C-reactive protein at 332 mg/L and procalcitonin at 1.25 ng/mL.

Taking into account the low platelet count, we used Fondaparinux (7.5 mg/day) for four days as an anticoagulant treatment, relayed by Rivaroxaban 30 mg/day for three weeks, then 20

mg/day for six months. Although the patient was asymptomatic, pulmonary scintigraphy showed a massive bilateral pulmonary embolism. Thrombophilia testing revealed a heterozygous R506Q FV Leiden mutation with no other abnormalities. Lupus anticoagulant, anti- β 2GPI antibodies, and anticardiolipin were negative. Oxygen (2L/min) was provided for a total of 6 days. Finally, the diagnosis of inherited thrombocytopenia was suspected because there was a family history of unexplained thrombocytopenia with at least six members known to be thrombocytopenic (Figure 1): her two sisters (Figure 1; III-1 and III-2); her father (Figure 1; II-4); two aunts (Figure 1; II-2 and II-3), and her grandmother (Figure 1; I-2). About the grandmother, we managed to retrieve the platelet count in 2015; they were at 32 G/L at the time. Interestingly, she suffered from 6 pulmonary embolisms (and was treated from 1995 with anti-vitamin K anticoagulant), but never suffered from any bleeding complications.

Sanger sequencing of the 5'UTR part of the ANKRD26 gene demonstrated a previously described heterozygous c-127 C>A mutation. Knowing that result, we decided to conduct familial genetic investigations. Interestingly,

Figure 1. Patient's family tree



the patient's grandmother was affected by refractory cytopenia with multilineage dysplasia. We evidenced two family members positive for this mutation: the maternal grandmother (Figure 1; I-2) and one aunt (Figure 1; II-2). Nine days after admission, the patient was discharged. Six months after this thromboembolic event, anticoagulant treatment was stopped with no further complications. The patient was lost to follow-up after this last medical consultation, due to a job transfer. This observation is, to our knowledge, the first case of a pulmonary thromboembolic event in a patient with an ANKR26 inherited mutation and a factor V Leiden heterozygous mutation.

Discussion. Thrombosis associated with inherited platelet disorders (IPDs) is rare. Girolami et al reviewed three different inherited platelet disorders with thrombotic events: two cases of inherited thrombocytopenia with increased MPV, i.e., MYH9 (Myosin Heavy Chain 9) (OMIM 155100) and Bernard-Soulier syndromes (BSS) (OMIM 231200), and a platelet function disorder with a normal MPV in Glanzmann thrombasthenia (GT, OMIM 273800).¹ In the majority of these cases, patients developed thrombotic events after identification of the inherited platelet disorders. To our knowledge, the present report is the first in which a venous thrombotic event resulted in the discovery of inherited thrombocytopenia (IT): ANKRD26-related thrombocytopenia (OMIM 18800). Nevertheless, these four platelet disorders differ from two other prothrombotic dysfunctional platelet disorders: the Wien-Penzing defect² and sticky platelet syndrome (SPS),³ characterized by the occurrence of venous or arterial thrombosis that usually reveals these platelet dysfunctions.

Thrombotic events described in the literature are mostly arterial: nine MYH9 patients^{1,4-5} and three BSS patients developed myocardial infarction, coronary arterial disease, and pons infarction stroke. In contrast, ten Glanzmann patients developed venous thrombosis,^{1,6} as did two MYH9 patients.¹ Traditional risk factors (long flight immobilization, old age, surgery, treatment) associated with venous thrombosis are evidenced in 36% of the cases, other risk factors (V Leiden or JAK2 mutations) in 28 %, unknown or undetected risk factors in 36%. In arterial thrombosis events, associated traditional risk factors (HTA, atrial fibrillation, hyperlipidemia,

elevated levels of homocysteinemia or cholesterol, atherosclerosis, smoking) are present in 67% of the cases and undetected or absent in 33%. As in our patient, heterozygous FV mutation was detected in three Glanzmann patients with recurrent deep venous thrombosis^{7,8} and a JAK2V617F mutation in an MYH9 patient with portal vein thrombosis.¹

The discrepancy between the macrothrombocytopenia group and Glanzmann patients for thrombotic events remains unexplained because thrombosis may occur whether a functional platelet defect is present (BSS, Glanzmann) or not (MYH9, ANKRD26). In addition, functional defects in Glanzmann and BSS patients are distinct: it has been suggested that the defective binding of Von Willebrand factor (alteration present in BSS) can protect from venous thrombosis, whereas defective binding of fibrinogen (seen in Glanzmann) protects more from arterial thrombosis.⁷ This hypothesis could not be totally applied to MYH9 syndrome or our case because these two IPDs have no functional defect. A recent, interesting report found no difference in thrombin potential generation in MYH9 patients with or without arterial thrombotic events, indicating that other factors than the low platelet count might have contributed to the thrombosis.⁵ However, few patients were tested in this study. One should also keep in mind not only that few patients who developed thrombosis have been described, but also that the frequency of the different forms of IT is variable. We cannot exclude that in the present report, the risk factors themselves induced venous thrombosis and that the association made herein might be fortuitous.

The IT type diagnosed in this report should also be described. In our patient's family, thrombocytopenia was a non-syndromic autosomal dominant form with an average MPV. In this disorder, morphologically platelets appeared normal but could be macrocytic,^{9,10} sometimes demonstrated with optical microscopy. Electron microscopy studies identified the presence of particulate cytoplasmic structures in ANKRD26 platelets and megakaryocytes of patients with mutations reflecting dysfunctional proteasome pathways.¹¹ In the group of IT patients with normal MPV, three genes must be sequenced first and foremost: the ANKRD26 gene (OMIM 188000), the RUNX1 gene mutated in the familial thrombocytopenic disorder with predisposition to

myeloid leukemia (OMIM 601399), and a recently described gene, ETV6, which confers a predisposition to lymphoid leukemia and solid tumors (OMIM 6000618;).¹² Platelet counts of different ANKRD26 patients published to date vary between 8 and 107 G/L, two patients having normal values.^{9,10} There are reports of transient normalization of platelet counts in the setting of an acute infection[],¹⁰ as observed in our patient, probably explained by the thrombopoietin level increase, usually found in inflammatory conditions.¹³ The bleeding syndrome is usually moderate, and numerous patients have undergone surgeries without platelet support and bleeding. No bone marrow analysis was performed for this diagnosis, but when previously performed, a dysmegakaryopoiesis is described, which contributes to the thrombocytopenia mechanism.¹⁰ Even if severe bleeding affects only a minority of patients, recent studies have pointed out the importance of IT genetic diagnosis.¹²

The majority of the mutations identified are single nucleotide substitutions in the 5'UTR part of the ANKRD26 gene: the most frequent mutations described were c-127 A>T, c-128G>A, and c-134G>A.^{9,10,14} One missense mutation in the coding region of the gene was also reported in one family.¹⁵ These mutations might result in the loss of two binding transcription factors that inhibit ANKRD26 expression in normal conditions and induce abnormal persistent activation of the ERK/MAP pathway, leading to the impaired pro-platelet formation and dysmegakaryopoiesis.¹⁶

References:

1. Girolami A, Sambado L, Bonamigo E, Vettore S, Lombardi AM. Occurrence of thrombosis in congenital thrombocytopenic disorders: a critical annotation of the literature. *Blood Coagul Fibrinolysis* 2013 Jan;24(1):18-22. <https://doi.org/10.1097/MBC.0b013e3283597634>
2. Sinzinger H, Kaliman J, O'Grady J. Platelet lipoxigenase defect (Wien-Penzing defect) in two patients with myocardial infarction. *Am J Hematol* 1991;36(3):202-205. <https://doi.org/10.1002/ajh.2830360308> PMID:1899965
3. Kubisz P, Stanciakova L, Stasko J, Dobrotova M, Sterenova M, Ivankova J, Holly P. The sticky platelet syndrome: an important cause of life-threatening thrombotic complications. *Expert Rev Hematol* 2016 Jan;9(1):21-35. Epub 2015 Dec 9. <https://doi.org/10.1586/17474086.2016.1121095>
4. Althaus K, Greinacher A. MYH-9 related platelet disorders. Strategies for management and diagnosis. *Transfus Med Hemother* 2010;37(5):260-267. Epub 2010 Sep 15. <https://doi.org/10.1159/000320335> PMID:21113248 PMID:PMC2980510
5. Zetterberg E, CarissonAlle MS, Najm J, Greinacher A. Thrombin generation in two families with MYH9 related platelet disorder. *Platelets* 2016;27(3):264-7. Epub 2015 Aug 6. <https://doi.org/10.3109/09537104.2015.1064882>
6. Nurden AT, Fiore M, Nurden P, Pilois X. Glanzmannthrombasthenia: a review of ITGA2B and ITGB3 defects with emphasis on variants, phenotypic variability and animal models. *Blood* 2011 Dec 1;118(23):5996-6005. Epub 2011 Sep 13. <https://doi.org/10.1182/blood-2011-07-365635>
7. Ten Cate H, Brandjes DPM, Smits PHM, Van Mourik JA. The role of platelets in venous thrombosis: a patient with glanzmann'sthrombasthenia and a factor V Leiden mutation suffering from deep venous thrombosis. *J ThrombHaem*2003; 1:394-395. <https://doi.org/10.1046/j.1538-7836.2003.00041.x> PMID:12871523
8. Rezende SM. Secondary prophylaxis with warfarin for recurrent thrombosis in a patient with Glanzmannthrombasthenia and F5 G1691A. *Br J Haematol*2012;156:144-145. <https://doi.org/10.1111/j.1365-2141.2011.08821.x> PMID:21848888
9. Pippucci T, Savoia A, Perrotta S, Pujol-Noix N, Noris P, Castegnaro G, et al. Mutations in the 5' UTR of ANKRD26, the ankyrin repeat domain 26 gene, cause an autosomal-dominant form of inherited thrombocytopenia, THC2. *Am J Hum Genet* 2011;88(1):115-120. <https://doi.org/10.1016/j.ajhg.2010.12.006> PMID:21211618 PMID:Cid:PMC3014357
10. Noris P, Perrotta S, Seri M, Pecci A, Gnan C, Loffredo G et al. Mutations in ANKRD26 are responsible for a frequent form of inherited thrombocytopenia analysis of 78 patients from 21 families. *Blood* 2011;117(34):6673-6680. <https://doi.org/10.1182/blood-2011-02-336537> PMID:21467542
11. Necchi V, Balduini A, Noris P, Barozzi S, Sommi P, Di Buduo C et al. Ubiquitin/proteasome rich particulate cytoplasmic structures (PaCs) in the platelets and megakaryocytes of ANKRD26-related

Today, it is well established that some ITs are characterized by increased risk of acquiring additional disorders over time that are much more relevant for patients than thrombocytopenia itself. Patients with ANKRD26-related thrombocytopenia have a propensity to develop myeloid malignancies.^{17,18} Therefore, recognizing such patients is essential to provide genetic counseling and personalize follow-up, especially if hematological malignancies occur.

Conclusions. This first report adds to previous observations and confirms that platelet defects do not protect from venous thrombosis, in particular, the ANKRD26 familial thrombocytopenia. It remains unexplained why thrombotic events appear in some inherited platelet disorders, but if we want to explain this association, this would require larger studies with more patients having rare platelet disorders which are not possible up to date. International guidelines for clinical and biological follow-up of these patients with inherited platelet disorders predisposing patients to hematological malignancies are therefore needed.

Authorship details. JG and RF conducted the literature review, drafted the manuscript, and made the figures.

Acknowledgements. The authors would like to thank Ms. Christine Nguyen for her technical assistance.

- thrombocytopenia. *ThrombHaemost* 2013;109 :263-71. <https://doi.org/10.1160/TH12-07-0497> PMID:23223974
12. Balduini CL, Savoia A, Seri M. Inherited thrombocytopenias frequently diagnosed in adults. *JThrombHaemost* 2013;11(6):1006-19. <https://doi.org/10.1111/jth.12196> PMID:23510089
 13. Cerutti A, Custodi P, Duranti M, Cazzola M, Balduini CL. Circulating thrombopoietin in reactive conditions behaves like an acute phase reactant. *Clin Lab Haematol*1999;21(4):271-275. <https://doi.org/10.1046/j.1365-2257.1999.00226.x> PMID:10583330
 14. Marquez R, Hantel A, Lorentz R, Neistadt B, Wong J, Churpek JE et al. A new family with a germline ANKRD26 mutation and predisposition to myeloid malignancies. *Leuk Lymphoma* 2014;55:2945-6. <https://doi.org/10.3109/10428194.2014.903476> PMID:24628296 PMCid:PMC4206674
 15. Al Daama SA, Housawi Y, Dridi W, Sager M, Otieno FG et al. A missense mutation in ANKRD26 segregates with thrombocytopenia. *Blood* 2013;122:481-2. <https://doi.org/10.1182/blood-2013-03-489344> PMID:23869080
 16. Bluteau D, Balduini A, Balayn N, Currao M, Nurden P, Deswarte C et al. Thrombocytopenia associated mutations in the ANKRD26 regulatory region induce MAPK hyperactivation. *J Clin Invest* 2014;124(2):580-91. <https://doi.org/10.1172/JCI71861> PMID:24430186 PMCid:PMC3904625
 17. Noris P, Favier R, Alessi MC, Geddis AE, Kunishima S, Heller PG, et al. ANKRD26-related thrombocytopenia and myeloid malignancies. *Blood* 2013;122(11):1987-9. <https://doi.org/10.1182/blood-2013-04-499319> PMID:24030261
 18. Babushok DV, Bessler M and Olson T. Genetic predisposition to myelodysplastic syndrome and acute myeloid leukemia in children and young adults. *Leuk Lymphoma* 2016; 57(3):520-36 <https://doi.org/10.3109/10428194.2015.1115041> PMID:26693794 PMCid:PMC4798888