



Case Report

COVID-19 post Hematopoietic Cell Transplant, a Report of 11 Cases from a Single Center

Alfadil Haroon, Momen Alnassani, Mahmoud Aljurf, Syed Osman Ahmed, Marwan Shaheen, Amr Hanbli, Naeem Chaudhari, Riad El Fakih.

Oncology Centre, King Faisal Specialist Hospital and Research Centre, Riyadh, KSA.

Competing interests: The authors declare no conflict of Interest.

Abstract. In late 2019 the coronavirus disease-2019 (COVID-19) pandemic caused by SARS Coronavirus 2 (SARS-CoV-2) started in Wuhan, China. Life has changed radically since then. Data emerging from the first hit countries show a tendency for a complicated course and higher mortality in some subgroups of infected patients. Cancer patients are immunosuppressed from their disease and the therapy they receive. Hematopoietic cell transplant (HCT) recipients are a subgroup of patients that are severely immunocompromised and may be at an even higher risk of a complicated course during this infection. Reports describing the course of these patients with COVID-19 disease are limited. We herein report the onset, progression, and outcome of 11 sequential cases of HCT recipients infected by SARS-CoV-2 treated in our center. The patients' age ranged from 17 to 60 years, the duration from transplant to infection ranged from day +5 to 192 months, six patients were post-allo-HCT, four post-auto-HCT, and one had both allo and auto-HCT. The presenting symptoms were not different from other viral illnesses. The majority (seven patients) had mild COVID-19 stage, while 3 had a moderate stage on presentation. None of the patients required oxygen supplementation nor mechanical ventilation.

Keywords: Coronavirus; COVID-19; SARS-CoV-2; Hematopoietic cell transplant; Bone marrow transplant; Stem cell transplant; Multiple myeloma; Acute lymphoblastic leukemia; Lymphoma.

Citation: Haroon A., Alnassani M., Aljurf M., Ahmed S.O., Shaheen M., Hanbli A., Chaudhari N., El Fakih R. COVID-19 post hematopoietic cell transplant, a report of 11 cases from a single center. *Mediterr J Hematol Infect Dis* 2020, 12(1): e2020070, DOI: <http://dx.doi.org/10.4084/MJHID.2020.070>

Published: September 1, 2020

Received: July 21, 2020

Accepted: August 25, 2020

This is an Open Access article distributed under the terms of the Creative Commons Attribution License (<https://creativecommons.org/licenses/by-nc/4.0>), which permits unrestricted use, distribution, and reproduction in any medium, provided the original work is properly cited.

Correspondence to: Alfadil Haroon, MD. Oncology Centre, KFSHRC, Section of Adult Hematology/HSCT, PO Box 3354, Riyadh, 11471, Saudi Arabia. E-mail: halfadil@kfshrc.edu.sa or fadil_130@hotmail.com
Riad El Fakih, MD. Oncology Centre, KFSHRC, Section of Adult Hematology/HSCT. PO Box 3354, Riyadh, 11471, Saudi Arabia. E-mail: riadfakih@hotmail.com or relfakih1@kfshrc.edu.sa

Introduction. The coronavirus disease-2019 (COVID-19) pandemic caused by SARS Coronavirus 2 (SARS-CoV-2), was first noted in Wuhan, China, in December 2019 and has since spread worldwide. At the time of writing this report, more than 23 million cases and 800 thousand COVID-19-related deaths have been confirmed by the world health organization(WHO) (<https://covid19.who.int/> accessed on August 24, 2020). Efforts are ongoing to understand every aspect of the virus, the host, and to develop an effective therapy or

vaccine.^{1,2} Although the majority of infected patients have mild disease, critical illness occurs in about 6.1% of affected patients. People at risk for severe outcome and death include those older than 60 years and those with comorbid disease states such as hypertension (HTN), chronic cardiac disease, chronic respiratory disease, chronic kidney disease (CKD), cardiovascular disease, diabetes mellitus (DM), cancer and immunosuppressed patients.³ Data emerging about cancer patients show that these patients have an

increased risk of complications and intensive care unit (ICU) admission.⁴ Hematopoietic cell transplant (HCT) patients are severely immune-compromised, and their course with COVID-19 is expected to be complicated. We herein report 11 cases of COVID-19 in post HCT patients.

Case 1. A 36 -years-old man was diagnosed with Philadelphia positive B-cell acute lymphoblastic leukemia (ALL) with no central nervous system (CNS) involvement in early March 2019. He was treated with daily dasatinib, weekly vincristine, and dexamethasone twice weekly. He was then treated with methotrexate and Ara-c and achieved complete molecular remission by polymerase chain reaction (PCR). Subsequently, he underwent allogeneic peripheral blood matched sibling HCT with cyclophosphamide (Cy) and total body irradiation (TBI) myeloablative conditioning (MAC) in July 2019. The course was complicated by grade II, steroid-responsive, acute gut graft versus host disease (GVHD), and cytomegalovirus (CMV) reactivation. He remains in complete molecular remission, and cyclosporine (CSA) was discontinued in March 2020 (day 237 post HCT). He is currently on prophylactic acyclovir and Bactrim. Early June 2020, he developed low grade fever of 37.9 Celsius (C) and fatigue. He tested positive for SARS-Cov2 infection by real-time Polymerase Chain Reaction (RT-PCR) on June 11, 2020 (day 323 post HCT). He did not have any further fever after June 12. He only received as needed acetaminophen. Repeat nasal SARS-Cov2 PCR on August 20, 2020, was negative, and his SARS-Cov2 total antibody test was reactive.

Case 2. A 29-years-old man was diagnosed with Philadelphia negative pre B ALL with no CNS involvement in August 2017. He was treated with a pediatric-inspired protocol and achieved remission; however, he had isolated CNS relapse while on maintenance therapy. He received salvage chemotherapy with fludarabine and Ara- C, and upon remission, he was consolidated with matched sibling allo-HCT using MAC with Cy/TBI; GVHD prophylaxis consisted of methotrexate and CSA. His course was complicated by grade II, steroid-responsive acute gut and skin GVHD as well as CMV colitis. Day 170 post HCT (June 5, 2020) while he was on tapering tacrolimus, he developed fever, cough, headache, runny nose followed by loss of taste and smell. He tested positive by PCR for SARS-Cov2 infection. Chest x-ray showed small faint ground-glass opacity in the left lower lung zone. Tacrolimus was stopped, and he was treated with ceftriaxone, hydroxychloroquine(HCQ), and azithromycin. He improved after 7days and was discharged. Repeat nasal SARS-Cov2 PCRs on July 8, 2020, were negative, and his SARS-Cov2 total antibody test was reactive on July 25, 2020. Unfortunately, on

August 7, 2020, he was diagnosed with relapsed ALL, and currently, he is receiving blinatumomab salvage.

Case 3. A 60-years-old man was diagnosed with IgG kappa multiple myeloma (MM) in 2002. He received induction therapy followed by autologous HCT with melphalan MAC in August 2002. He relapsed 15 months after auto-HCT. He received another induction followed by allo-HCT in 2004 after achieving deep remission. His conditioning was reduced intensity with fludarabine/TBI. In 2013 he had a biochemical relapse, so he was re-induced with bortezomib based therapy followed by donor lymphocyte infusion (DLI). He had another relapse in December 2019 and has been on dexamethasone 32 mg weekly since then. In May 2020, he developed fever and body aches after contact with a confirmed case of COVID-19, and he tested positive by PCR for SARS-Cov2 infection. He was admitted and treated symptomatically only and then discharged three days after admission after symptom-improvement. Repeat nasal SARS-Cov2 PCR on August 15, 2020, was negative, and his SARS-Cov2 total antibody test was reactive on August 16, 2020.

Case 4. A 56 -years-old woman known to have hypothyroidism, hypertension (HTN), diabetes mellitus (DM), and atrial fibrillation (AF) was diagnosed with Multiple myeloma (MM) in November 2013. She achieved partial remission (PR) after induction and underwent auto-HCT in July 2014 with melphalan MAC conditioning. She was on bortezomib maintenance, but she progressed and was started on Revlimid but could not tolerate it. In March 2019, she was started on carfilzomib and dexamethasone and achieved a near CR after six cycles. Her therapy was held since December 2019 due to diarrhea. Late May 2020, she developed malaise, fatigue, headache, and fatigue. She tested positive by PCR for SARS-Cov2 infection. She was hospitalized and treated with ceftriaxone (she did not receive HCQ nor azithromycin due to her comorbidities and the drug-drug interaction with her home medications). She recovered and was discharged after nine days of hospitalization. Repeat nasal SARS-Cov2 PCR on August 20, 2020, was negative, and his SARS-Cov2 total antibody test was reactive.

Case 5. A 58-year-old man known to have morbid obesity, dyslipidemia, hypothyroidism, and a remote history of pleural Tuberculosis (TB) was diagnosed with IgG kappa multiple myeloma in July 2015. He received induction with bortezomib, lenalidomide, and dexamethasone followed by auto-HCT with melphalan MAC conditioning after achieving a very good partial response (VGPR). He was maintained on lenalidomide with dexamethasone, but he relapsed in December 2017 and was treated with carfilzomib, lenalidomide, and dexamethasone. In late May 2020, while on therapy, he developed a sore throat, fever, and runny nose. He tested

positive by PCR for SARS-Cov2 infection. He recovered well after seven days of initial symptoms. Repeat nasal SARS-Cov2 PCR on August 20, 2020, was negative, and his SARS-Cov2 total antibody test was reactive.

Case 6. A 26-year-old man was diagnosed with classical Hodgkin lymphoma (cHL) stage IIB in May 2018. He was started on ABVD (Doxorubicin, Bleomycin, Vinblastine, and Dacarbazine) and escalated to BEACOPP due to progression after two cycles of ABVD. He received a total of 4 BEACOPP followed by radiation, but he relapsed in May 2019. He received salvage ESHAP (Methylprednisolone, Cisplatin, Etoposide, and Cytarabine) with brentuximab vedotin for three cycles, followed by MAC auto-HCT with BEAM (carmustine, etoposide, cytarabine, and melphalan) conditioning in September 2019, after auto-HCT he was on maintenance brentuximab vedotin. In June 2020, he complained about a loss of smell and tested positive by PCR for SARS-Cov2 infection. He was treated symptomatically with no admission to the hospital. His nasal SARS-Cov2 PCR was not repeated, and his SARS-Cov2 total antibody test was not done.

Case 7. A 21-year-old man was diagnosed with T-cell lymphoid blast crisis with underlying chronic myeloid leukemia (CML) in May 2019. He was treated with a pediatric chemotherapy regimen plus tyrosine kinase inhibitor (TKI) and achieved major molecular remission after induction. He underwent haploidentical HCT in June 2020 with fludarabine/TBI MAC conditioning along with rabbit antithymocyte globulin (ATG) and post-transplant cyclophosphamide with CSA and Mycophenolate Mofetil (MMF) for GVHD prophylaxis. On day zero of transplant, his donor (father) tested positive for SARS-Cov2 by PCR. The collection was postponed for one day in an attempt to find another donor; in the meantime, the donor was given HCQ and azithromycin. All his other family members tested positive for SARS-Cov2 by PCR, and the decision was made to proceed with the initial donor apheresis. SARS-Cov2-PCR was negative on the apheresis product. The patient's SARS-Cov2-PCR was negative before admission and on day +1 after transplant. On day +5 post-HCT, the patient's SARS-Cov2-PCR from nasopharyngeal swab came back positive, but the patient was asymptomatic. He was treated with azithromycin and HCQ, and on day +10 post-HCT, one dose of tocilizumab was given secondary to elevated inflammatory markers (ferritin and interleukin 6). Platelet engrafted on day+9, while neutrophils engrafted on day+23. On day +12 post-HCT, SARS-Cov2-PCR from nasopharyngeal swab was repeated and was positive. On day +14, the post-HCT patient developed culture-negative neutropenic fever with further

elevation in the inflammatory markers; the second dose of tocilizumab was given, and he was started on meropenem, but he was still asymptomatic besides fever, and specifically, he did not develop respiratory symptoms. On day+18, CT chest showed left lung ground-glass opacities. He then developed hemophagocytic lymphohistiocytosis (HLH) and macrophage activation syndrome (MAS). He was treated with dexamethasone and Intravenous immune globulin (IVIG) for four days, and ruxolitinib was added due to a continuous rise in ferritin. After the addition of ruxolitinib, his inflammatory markers and liver enzymes decreased figure (1 and 2). Currently, he fully recovered and is asymptomatic; however, his repeat nasal SARS-Cov2 PCR on August 5, 2020, was definite, and his SARS-Cov2 total antibody test was non-reactive.

Case 8. A 17-year-old female patient was diagnosed with Philadelphia positive B cell ALL in August 2018. She received dasatinib, vincristine, rituximab and dexamethasone induction and achieved deep molecular remission followed by haploidentical-HCT from her brother donor using fludarabine/TBI MAC conditioning in April 2019. Her course was complicated by falling chimerism and eventually autologous recovery with donor chimerism reaching zero on day 90 post-HCT. Her immunosuppression was stopped, and she was started on maintenance dasatinib. In July 2020, she tested positive for SARS-Cov2 by PCR after contact with a positive case. She is currently asymptomatic and continuing on dasatinib and acyclovir. Repeat nasal SARS-Cov2 PCR on August 20, 2020, was negative, but the SARS-Cov2 total antibody test was not done.

Case 9. A 35-year-old man was diagnosed with translocation (11;19) acute myeloid leukemia(AML) in April 2019. He received induction therapy followed by haploidentical-HCT after achieving remission in May 2019. His conditioning was thiotepa, fludarabine, and busulfan MAC along with rabbit ATG, cyclosporine, and MMF for GVHD prophylaxis. His transplant course was complicated with perianal abscess, CMV reactivation, collagenous colitis, and acute skin GVHD. In July 2020, while he was on a tapering dose of prednisone for his GVHD, he presented with fatigue, fever, and productive cough and tested positive for SARS-Cov2 by PCR. He had bilateral patchy ground-glass opacities on chest x-ray and was started on azithromycin, ceftriaxone, and HCQ. Currently, he is doing well and asymptomatic; repeat nasal SARS-Cov2 PCR on August 7, 2020, was negative, but the SARS-Cov2 total antibody test was done on July 14, and August 17, 2020, and was non-reactive.

Case 10. A 49-year-old woman was diagnosed with AML with (Fms-like tyrosine kinase3-Internal tandem duplication) FLT3-ITD positive,

Nucleophosmin (NPM1) positive and Isocitrate dehydrogenase2 (IDH2) positive mutations in mid-June 2019. She received induction therapy with FLT3 inhibitor and achieved remission. She underwent a matched sibling donor transplant in November 2019 using MAC busulfan and fludarabine. Post-HCT, she was on sorafenib maintenance for six months only (stopped because of recurrent leukopenia). On day +206 post-HCT, she developed a cough, chest pain, shortness of breath, and sore throat; her SARS-Cov2 PCR from nasopharyngeal swab tested positive. She was hospitalized, treated symptomatically, and discharged in stable condition after ten days. Her nasal SARS-Cov2 PCR was not repeated, and her SARS-Cov2 total antibody test was not done.

Case 11. A 58-year-old woman, known to have DM, HTN, chronic kidney disease, hypothyroidism, and bronchial asthma, was diagnosed with stage IVB diffuse large B cell lymphoma (DLBCL), in May 2019. She received six cycles of reduced dose R-CHOP (Rituximab, Cyclophosphamide, Doxorubicin, Vincristine, and Prednisone) and achieved complete remission. She relapsed three months after finishing therapy. She then received three cycles of Rituximab-ESHAP followed by myeloablative BEAM auto-transplant after achieving partial remission with RESHAP. Her transplant was in mid-March 2020. In June 2020, she developed fever and shortness of breath; she tested positive for SARS-Cov2 by PCR; she reported contact with a positive case. She was treated with azithromycin, HCQ, and meropenem and recovered well. Repeat nasal SARS-Cov2 PCR on August 20, 2020, was negative, but the SARS-Cov2 total antibody test was not done.

Discussion. COVID-19 is a new disease with no approved therapies (except remdesivir in the United States and Japan, and tocilizumab in China) and lots of uncertainties. With uncertainty comes fear and anxiety, especially in subgroups of immunocompromised patients who may be at an increased risk of a complicated course during the infection. Efforts are ongoing to understand the impact of this viral infection in different patients' subgroups. Patients with cancer, and specifically with hematologic malignancies, seem to be at a higher risk for complications and death.⁴⁻¹⁰ With more than one and a half million transplant-patients in the world, and around 90 thousand transplants carried out annually worldwide, a significant number of these patients are expected to develop this new viral infection.¹¹ The outcomes and the course of the infection in this specific subgroup of patients are unknown. So far, we were able to find one case report of an AML patient who was diagnosed with COVID-19 infection eight months after allogeneic transplant while still on cyclosporine. The patient presented with fever, sore

throat, and runny nose and was treated with lopinavir/ritonavir, steroids, and immunoglobulins but unfortunately developed ARDS and respiratory failure and died 22 days after the onset of symptoms.¹² In another case report, a 59-year-old man developed severe COVID-19 infection with ARDS a year after matched sibling transplant for myelofibrosis. The patient had significant comorbidities in addition to steroid-refractory cGvHD. Despite therapy with lopinavir-ritonavir, he progressed to ARDS and respiratory failure requiring mechanical ventilation. He received multiple antibiotics during his hospitalization. He improved significantly and was discharged after increasing the dose of ruxolitinib that he was taking for cGvHD (he was on 5 BID and was increased to 10 mg BID).¹³ Additionally, a case series (8 patients) was recently reported from a Spanish pediatric transplant group.¹⁴ The most common symptom was fever, 5/8 patients had radiographic abnormalities, 5/8 patients were hospitalized, and two of them needed intensive care. Six patients received HCQ, and the two patients admitted to ICU received in addition to HCQ, azithromycin, remdesivir, lopinavir/ritonavir, tocilizumab, siltuximab, and Anakinra. One of the ICU patients died of alveolar hemorrhage and the others survived.

We report 11 consecutive patients from our center with post hemopoietic cell transplant COVID-19 infection (table 1). Patients' age ranged from 17 to 60; the duration from transplant to infection ranged from day +5 to 192 months, six patients were post-allo-HCT, four post-auto-HCT, and one had both allo and auto-HCT. Three patients were transplanted for ALL, 3 for MM, 2 for AML, 1 for CML with blast crisis, 1 for DLBCL, and one for classic HL. Six patients had other comorbidities (3 DM, 2 GVHD, and one obesity); only one patient was a smoker. Seven patients were on some form of therapy either for their primary disease or for post-transplant immunosuppression or maintenance (3 on steroids, two on calcineurin inhibitors, one on brentuximab, and one on dasatinib). The presenting symptoms were not different from other viral illnesses with six patients having a fever; four had fatigue, three had a cough, two had headaches, 3 with shortness of breath, 2 with a runny nose, 1 with loss of smell and two patients were asymptomatic (screened for having contact with positive cases). The majority (seven patients) had mild COVID-19 stage (two of them later progress to moderate stage).

In contrast, three had a moderate stage on presentation, six patients were hospitalized, and five were isolated at home. Six patients did not receive any therapy other than supportive care; four patients were treated with a combination of hydroxychloroquine (HCQ), azithromycin, and either ceftriaxone (two) or meropenem (two), one patient was treated with ceftriaxone alone. Of note, all the patients were still on acyclovir prophylaxis as a part of their routine transplant

Table 1. Summarizes the clinical and laboratory profile of all the cases.

	Case 1	Case 2	Case 3	Case 4	Case 5	Case 6	Case 7	Case 8	Case 9	Case 10	Case 11
age	36 years	29 years	60 years	56 years	58 years	27 years	21 years	17 years	35 years	49 years	58 years
Sex	Male	Male	Male	Female	Male	Male	Male	Female	Male	Female	Female
Hematological disease	B-cell ALL	B-cell ALL Isolated CNS Relapsed	Multiple myeloma	Multiple myeloma	Multiple myeloma	cHL	CML with T cell lymphoid blast crisis	B cell ALL	AML	AML	DLBCL
Stem cell Transplant type	Allo HCT	Allo HCT	Auto /Allo HCT	Auto HCT	Auto HCT	Auto HCT	Allo HCT	Allo HCT	Allo HCT	Allo HCT	Auto HCT
Time from HCT to COVID-19 symptoms	10.7 month (+323days)	5.6 month (+170 day)	192 month	71 month	53 month	9.1 month(+275days)	day +5	13.8month (+415 days)	14 month (421 days)	6.8 month (+206 days)	2 month (+60 days)
Prophylactic antimicrobials	Acyclovir ,Bactrim	Acyclovir ,Bactrim	Acyclovir ,Bactrim	Acyclovir ,Bactrim	Acyclovir ,Bactrim	Acyclovir ,Bactrim	Acyclovir	Acyclovir	Acyclovir posaconazole	Acyclovir bactrim	Acyclovir Bactrim fluconazole
Immunosuppressant	non	tacrolimus	Dexamethasone	non	Dexamethasone Revlimid	Brentuximab	CSA,MMF	Dasatinib	prednisolone 15mg	non	non
Disease status	remission	Relapsed	Relapsed	remission	remission	remission	Unknown	remission	remission	remission	remission
COVID-19 Symptoms	fever and fatigue	fever, runny nose, headache and cough	Fever, headache, fatigue and body aches	headache , fatigability and SOB	Sore throat, fever and runny nose	Loss of smell	asymptomatic	asymptomatic	generalized fatigue, fever and productive cough	Cough, SOB Sore throat and Chest pain	Fever, SOB
comorbidity	no	aGVHD skin	GVHD gut	DM,HTN,AF	morbid obesity , Hypothyroidism	no	no	no	DM	no	DM,HTN, CKD Hypothyroidism
COVID-19 stage	mild	moderate	mild	moderate	mild	mild	moderate	mild	moderate	moderate	moderate
Hospital admission	no	yes	yes	yes	no	no	no	no	yes	yes	yes
Mechanical ventilation required	no	no	no	no	no	no	no	no	no	no	no
COVID-19 treatment	Symptomatic treatment	Azithromycin, HCQ,Ceftriaxone	non	Ceftriaxone	symptomatic management	non	Azithromycin,HCQ meropenem	non	Azithromycin,HCQ , Ceftriaxone	symptomatic management	Azithromycin ,HCQ meropenem
Oxygen therapy required	no	no	no	no	no	no	no	no	no	no	no
Chest X ray finding	Not indicated	ground-glass opacity in the left lower lung zone	Not indicated	opacity in right lower zone	Not indicated	Not indicated	multifocal patchy ground-glass opacities in left lung	Not indicated	bilateral patchy ground glass opacities	Not indicated	left lower lobe ground-glass opacities
WBCs (3.9-11.0) 10 ⁹ /L	NA	4.04	NA	2.86	NA	NA	0.07	6.8	4.69	NA	3.2
lymphocyte (1.5-4.3) 10 ⁹ /L	NA	2.47	NA	0.8	NA	NA	NA	3.1	1.25	NA	1.85

Neutrophils (30.0-70.0) 10 ⁹ /L	NA	1.36	NA	2.1	NA	NA	NA	3.0	2.4	NA	2./3
COVID-19 PCR follow up	negative 70 days after confirming the infection	negative 33 days after confirming the infection	negative 86 days after confirming the infection	negative 81 days after confirming the infection	negative 91 days after confirming the infection	not done	positive 42 days after confirming the infection	negative 34 days after confirming the infection	negative 48 days after confirming the infection	not done	negative 65 days after confirming the infection
SARS-Cov2 Total Antibody Screening	Reactiv 70 days after confirming the infection	Reactiv 33 days after confirming the infection	Reactive 86 days after confirming the infection	Reactiv 81 days after confirming the infection	Reactiv 91 days after confirming the infection	not done	Non Reactive 42 days after confirming the infection	not done	Non Reactive 48 days after confirming the infection	not done	Not done

DM-diabetes mellitus, HTN-hypertension, CSA-cyclosporine, ALL-acute lymphoblastic leukemia, auto-autologous, HCT-hematopoietic cell transplant, AF-atrial-fibrillation, MM-Multiple myeloma, SOB-shortness of breath, GVHD-graft versus host disease, HGB-hemoglobin , NA-not available .

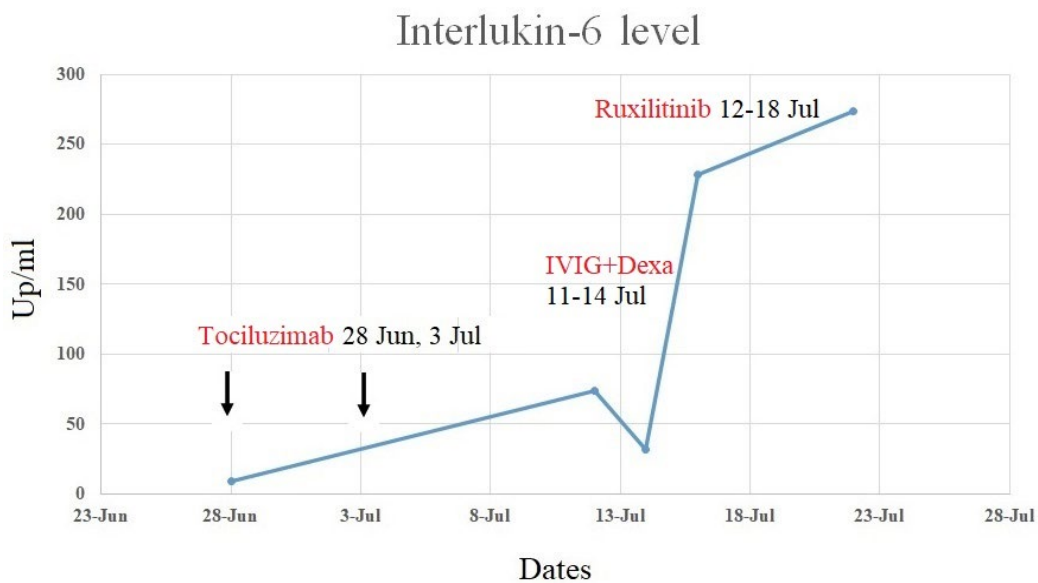
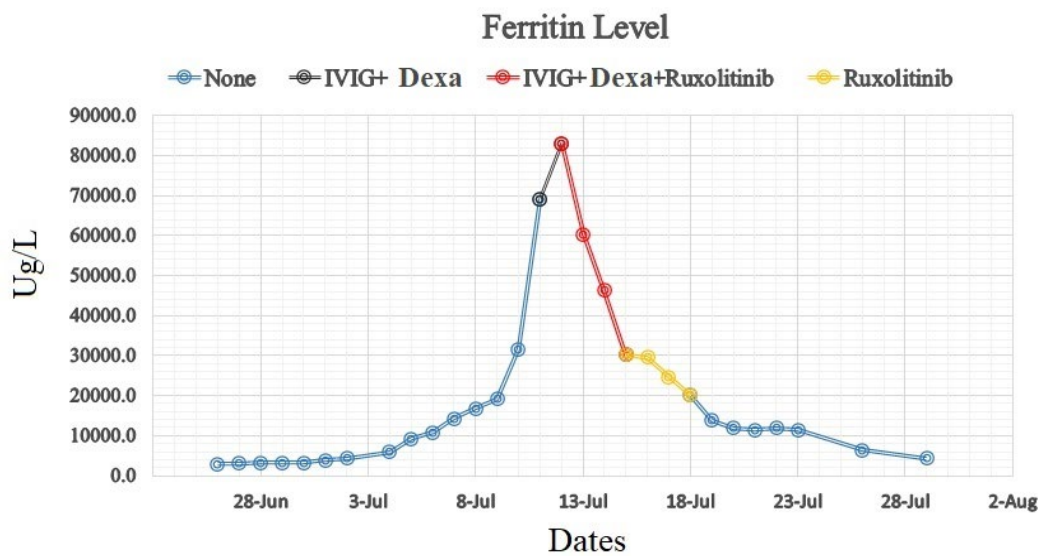


Figure 1. Case number 7 ferritin and IL-6 level. Dexa-dexamethasone IVIG- intravenous immune globulin

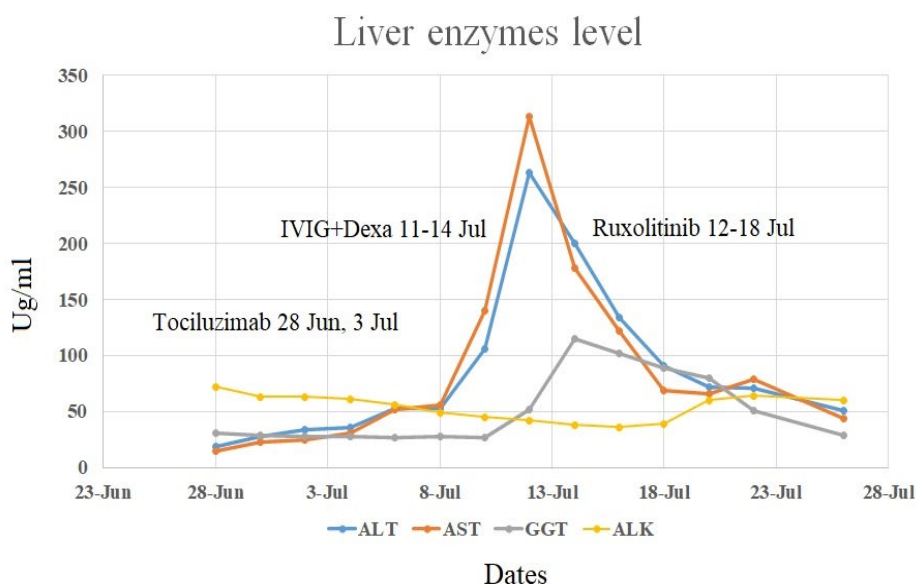


Figure 2. Case number 7 liver enzyme level.

care; seven were on Bactrim prophylaxis and one on posaconazole. None of the patients required oxygen supplementation nor mechanical ventilation. The patient case number 7 tested positive on day +5 of haplo-HCT; his donor tested positive on the day of donation as well as many other family members. The harvested product was negative by PCR, and his nasopharyngeal swab was negative on day +1 but converted to positive on day +5. We assume that he acquired the infection through transmission from family members rather than from the apheresis product. A study from Singapore demonstrated that the virus could be found in the blood of infected patients in around 8% of the cases.¹⁵ Recently a donor with a positive PCR from nasopharyngeal swab was used to donate his sister, and the recipient did not acquire the infection; the harvested product was tested by PCR and was negative as well.¹⁶

Conclusions. Our patients surprisingly did extremely well; however, the number of cases is small, and drawing firm conclusions is impossible. Whether

acyclovir plays any role or not in these patients is unclear; currently, no data support the use of acyclovir for COVID-19 infection. Transplant patients are heterogeneous, complex, and their immune reconstitution is multifactorial and depends on the time from transplant and the presence of GVHD; these are all crucial variables that can affect the course of infection in these patients. Large numbers of patients are needed to delineate the risk factors and variables affecting the outcomes and better to understand the impact of this virus on transplant patients. We urge healthcare professionals to report their experience to understand the effect of COVID-19 on bone marrow transplant recipients and to serve this subgroup of patients better. Finally, awaiting a better understanding of this infection, we as providers for this group of vulnerable patients are urged to take necessary measures to ensure clear guidance is conveyed to our patients about the importance of preventive measures until a better understanding or therapy/vaccine of the disease is in hands.

References:

- World Health O. Informal consultation on prioritization of candidate therapeutic agents for use in novel coronavirus 2019 infection. January 24 2020. 2020.
- Lurie N, Saville M, Hatchett R, Halton J. Developing Covid-19 vaccines at pandemic speed. *New England Journal of Medicine* 2020;382(21):1969-1973. <https://doi.org/10.1056/NEJMp2005630> PMID:32227757
- Huang C, Wang Y, Li X, Ren L, Zhao J, Hu Y, Zhang L, Fan G, Xu J, Gu X. Clinical features of patients infected with 2019 novel coronavirus in Wuhan, China. *The lancet* 2020;395(10223):497-506. [https://doi.org/10.1016/S0140-6736\(20\)30183-5](https://doi.org/10.1016/S0140-6736(20)30183-5)
- Miyashita H, Mikami T, Chopra N, Yamada T, Chernyavsky S, Rizk D, Cruz C. Do patients with cancer have a poorer prognosis of COVID-19? An experience in New York City. *Annals of Oncology* 2020. <https://doi.org/10.1016/j.annonc.2020.04.006> PMID:32330541 PMCid:PMC7172785
- Guan WJ, Liang WH, Zhao Y, Liang HR, Chen ZS, Li YM, Liu XQ, Chen RC, Tang CL, Wang T and others. Comorbidity and its impact on 1590 patients with COVID-19 in China: a nationwide analysis. *Eur Respir J* 2020;55(5). <https://doi.org/10.1183/13993003.01227-2020> PMID:32341104 PMCid:PMC7236831
- Miyashita H, Mikami T, Chopra N, Yamada T, Chernyavsky S, Rizk D, Cruz C. Do patients with cancer have a poorer prognosis of COVID-19? An experience in New York City. *Ann Oncol* 2020. <https://doi.org/10.1016/j.annonc.2020.04.006> PMID:32330541 PMCid:PMC7172785
- He W, Chen L, Chen L, Yuan G, Fang Y, Chen W, Wu D, Liang B, Lu X, Ma Y and others. COVID-19 in persons with hematological cancers. *Leukemia* 2020. <https://doi.org/10.1038/s41375-020-0836-7>

- PMid:32332856 PMCID:PMC7180672
8. Gavillet M, Klappert JC, Spertini O, Blum S. Acute leukemia in the time of COVID-19. *Leukemia Research* 2020;92:106353. <https://doi.org/10.1016/j.leukres.2020.106353>
PMid:32251934 PMCID:PMC7138175
 9. Wang H, Zhang L. Risk of COVID-19 for patients with cancer. *The Lancet Oncology* 2020;21(4):e181. [https://doi.org/10.1016/S1470-2045\(20\)30149-2](https://doi.org/10.1016/S1470-2045(20)30149-2)
 10. Dai M, Liu D, Liu M, Zhou F, Li G, Chen Z, Zhang Z, You H, Wu M, Zheng Q. Patients with cancer appear more vulnerable to SARS-CoV-2: a multicenter study during the COVID-19 outbreak. *Cancer discovery* 2020;10(6):783-791. <https://doi.org/10.1158/2159-8290.CD-20-0422>
PMid:32345594 PMCID:PMC7309152
 11. Niederwieser D, Baldomero H, Atsuta Y, Aljurf M, Seber A, Greinix HT, Koh M, Worel N, Galeano S, Jaimovich G. One and half million hematopoietic stem cell transplants (HCT). Dissemination, trends and potential to improve activity by telemedicine from the Worldwide Network for Blood and Marrow Transplantation (WBMT). *American Society of Hematology* Washington, DC; 2019. <https://doi.org/10.1182/blood-2019-125232>
 12. Huang J, Lin H, Wu Y, Fang Y, Kumar R, Chen G, Lin S. COVID-19 in posttransplant patients a report of 2 cases. *American Journal of Transplantation* 2020. <https://doi.org/10.1111/ajt.15896>
PMid:32243697
 13. Saraceni F, Scortechini I, Mancini G, Mariani M, Federici I, Gaetani M, Barbatelli P, Minnucci M, Bagnarelli P, Olivieri A. Severe COVID-19 in a patient with chronic graft-versus-host disease after hematopoietic stem cell transplant successfully treated with ruxolitinib. *Transplant Infectious Disease* 2020:e13401. <https://doi.org/10.1111/tid.13401>
PMid:32629531 PMCID:PMC7361240
 14. Vicent MG, Martinez AP, Del Castillo MT, Molina B, Sisini L, Moron-Cazalilla G, Diaz MA. COVID-19 in pediatric hematopoietic stem cell transplantation: The experience of Spanish Group of Transplant (GETMON/GETH). *Pediatric blood & cancer* 2020. <https://doi.org/10.1002/pbc.28514>
PMid:32573924 PMCID:PMC7361142
 15. Young BE, Ong SWX, Kalimuddin S, Low JG, Tan SY, Loh J, Ng O-T, Marimuthu K, Ang LW, Mak TM. Epidemiologic features and clinical course of patients infected with SARS-CoV-2 in Singapore. *Jama* 2020;323(15):1488-1494. <https://doi.org/10.1001/jama.2020.3204>
PMid:32125362 PMCID:PMC7054855
 16. Anurathapan U, Apiwattanakul N, Pakakasama S, Pongphitcha P, Thitithyanont A, Pasomsab E, Hongeng S. Hematopoietic stem cell transplantation from an infected SARS-CoV2 donor sibling. *Bone Marrow Transplantation* 2020:1-2. <https://doi.org/10.1038/s41409-020-0969-3>
PMid:32528121 PMCID:PMC7289075