



**Case Report**

**The Diagnostic Pitfalls of Mucormycosis**

Margherita Mauro<sup>1</sup>, Giuliana Lo Cascio<sup>2</sup>, Rita Balter<sup>1</sup>, Ada Zaccaron<sup>1</sup>, Elisa Bonetti<sup>1</sup>, Virginia Vitale<sup>1</sup>, Matteo Chinello<sup>1</sup>, Massimiliano De Bortoli<sup>1</sup>, Paolo Brazzarola<sup>3</sup>, Costanza Bruno<sup>4</sup> and Simone Cesaro<sup>1</sup>.

<sup>1</sup> Pediatric Hematology Oncology, Department of Mother and Child, Azienda Ospedaliera Universitaria Integrata, Verona, Italy.

<sup>2</sup> Unità Operativa Complessa di Microbiologia e Virologia, Dipartimento di Patologia e diagnostica, Azienda Ospedaliera Universitaria Integrata, Verona, Italy.

<sup>3</sup> Endocrine Surgery Unit, Department of Surgery and Oncology, University and Hospital Trust of Verona, Verona, Italy.

<sup>4</sup> Department of Radiology, Radiology Institute, Verona, Italy.

**Competing interests:** The authors declare no conflict of Interest.

**Abstract. Background:** Invasive mucormycosis is a very aggressive fungal disease among immunocompromised pediatric patients caused by saprophytic fungi that belong to the order of the Mucorales.

**Case Report:** We describe a case of *Lichtheimia corymbifera* infection in a 15-year-old child with B-cell-Non-Hodgkin Lymphoma (B-NHL) involving lung, kidney and thyroid that initially was diagnosed as probable aspergillosis delaying the effective therapy for mucormycosis.

**Conclusions:** This case showed that also the intensive chemotherapy for B-NHL may represent a risk factor for mucormycosis infection. Liposomal amphotericin B and surgery remain the key tools for the successful treatment of this aggressive disease.

**Keywords:** Pediatric non Hodgkin lymphoma; Fungal infection; Mucormycosis.

**Citation:** Mauro M., Lo Cascio G., Balter R., Zaccaron A., Bonetti E., Vitale V., Chinello M., De Bortoli M., Brazzarola P., Bruno C., Cesaro S. The diagnostic pitfalls of mucormycosis. *Mediterr J Hematol Infect Dis* 2020, 12(1): e2020079, DOI: <http://dx.doi.org/10.4084/MJHID.2020.079>

**Published:** November 1, 2020

**Received:** September 8, 2020

**Accepted:** October 17, 2020

This is an Open Access article distributed under the terms of the Creative Commons Attribution License (<https://creativecommons.org/licenses/by-nc/4.0>), which permits unrestricted use, distribution, and reproduction in any medium, provided the original work is properly cited.

Correspondence to: Margherita Mauro, M.D. Pediatric Hematology Oncology, Azienda Ospedaliera Universitaria Integrata, Verona, Italy. Tel. +39-3408420257. E-mail: [mauro.margherita88@gmail.com](mailto:mauro.margherita88@gmail.com)

**Introduction.** Invasive mucormycosis is a very aggressive fungal disease among immunocompromised patients caused by saprophytic fungi ubiquitous in nature. They belong to the order of the Mucorales including *Rhizopus* species, *Mucor*, *Lichtheimia* (previously *Absidia*), *Cunninghamella*, *Rhizomucor*, *Apophysomyces* and *Saksenaea*.<sup>1,2</sup>

In pediatric patients, the risk factors include hematologic malignancy, hematopoietic stem cell transplant (HSCT), solid organ transplant, neutropenia, poorly controlled diabetes mellitus, use of corticosteroids, prematurity and trauma.<sup>3-5</sup>

The clinical presentations are rhino cerebral, pulmonary, gastrointestinal, cutaneous, and

disseminated disease. All clinical manifestations progress rapidly because of tissue angioinvasion leading to thrombosis and tissue necrosis.<sup>6,7</sup> Mortality ranges between 22% and 59% in different reports.<sup>1,2</sup>

We describe a case of *Lichtheimia corymbifera* infection in an adolescent with B-cell-Non-Hodgkin lymphoma (B-NHL) involving lung, kidney and thyroid that initially was diagnosed as probable aspergillosis, delaying the effective therapy for mucormycosis.

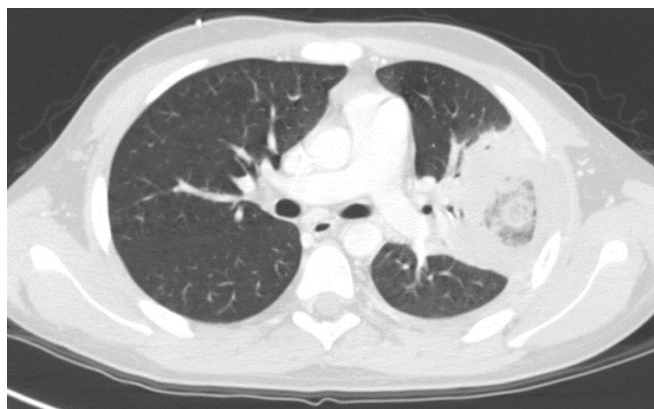
**Case Report.** A 15-year-old Caucasian boy was diagnosed with B-NHL involving lymph nodes, mediastinum and bones. The patient was treated

according to B-NHL-BFM (Berlin–Frankfurt–Munster) 1997 protocol combined with Rituximab.<sup>8</sup>

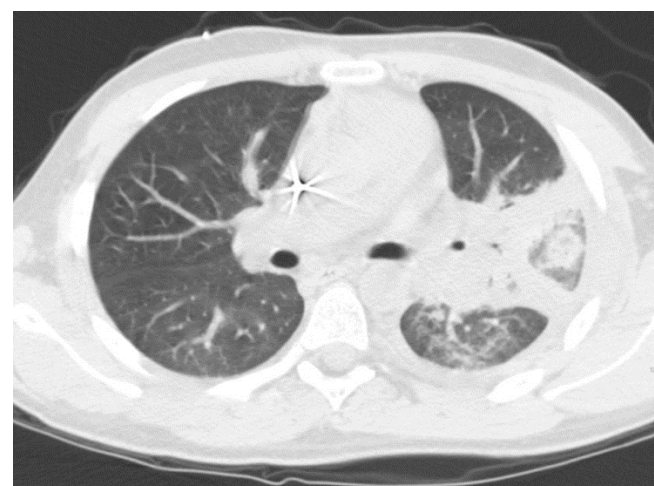
Seven days after the fifth chemotherapy course, the patient was hospitalized for fever (37.9°C), severe cytopenia (white blood cell count  $0.15 \times 10^9/L$ , neutrophils  $0 \times 10^9/L$ , platelet count  $23 \times 10^9/L$ , Hb 96 g/L), elevated C-reactive protein [C-RP] (92 mg/l), but normal procalcitonin [PCT] (0.33 ng/ml) and vital signs (blood pressure 124/69 mmHg, heart rate 79 beats per minute [bpm], peripheral oxygen saturation [SpO<sub>2</sub>] 97%). After drawing blood cultures from central line and peripheral vein, an empiric antibiotic treatment with ceftazidime, amikacin and teicoplanin was promptly initiated together with granulocyte colony stimulating factor (G-CSF), while prophylaxis with cotrimoxazole and fluconazole was continued. On day 4 tachypnea, dyspnea, hypoxemia (SpO<sub>2</sub> 80%), tachycardia (heart rate 150 bpm) and left hemithorax acute pain appeared together with an increase of CRP (440 mg/l) and PCT (3.13 ng/ml). On physical examination, lung auscultation revealed diminished breath sounds and rales over the left lung. The first set of blood cultures was negative as well as the second one and the blood samples for galactomannan (GM) and  $\beta$ -d-glucan (BDG) antigens. Lung computerized tomography (CT) showed a left extensive consolidation associated with pleural effusion (**Figure 1**).

Considering a possible fungal origin of pneumonia and the profound B-lymphocytopenia, micafungin (100 mg/day) was started and, in order to enhance the innate immunity, a 3-day course of intravenous IgM-enriched immunoglobulins was administered. On day 6 the fever disappeared while the neutrophils recovered over  $0.5 \times 10^9/L$ . On day 7, BDG was markedly positive ( $> 523$  pg/ml) while GM remained negative. On day 9, high fever reappeared associated with edema and hyperemia on the left neck. A second lung CT revealed a slight increment of the left lung consolidation (**Figure 2**). A neck ultrasound detected a swelling lesion in left thyroid lobe (19 x 19 mm) and an abdomen ultrasound found a nodule in the middle-superior part of the right kidney (25 x 22 mm). These nodular lesions, as well as the lung one, were intensely hypermetabolic on positron emission tomography (PET)-CT scan proving to have probably the same infectious origin. We performed a needle aspiration of the thyroid lesion showing only the presence of a suppurative process. Blood cultures and serum GM were again negative whereas serum BDG value returned into normal range.

The antifungal therapy was enhanced adding voriconazole to micafungin, while the antibiotic therapy was modified introducing meropenem and replacing ceftazidime and amikacin with meropenem. Despite this, the fever persisted with a CRP rising to 425.8 mg/L on day 11. On day 17 the patient underwent a bronchoalveolar lavage (BAL) that resulted negative for bacteria, fungi, *Mycobacterium*



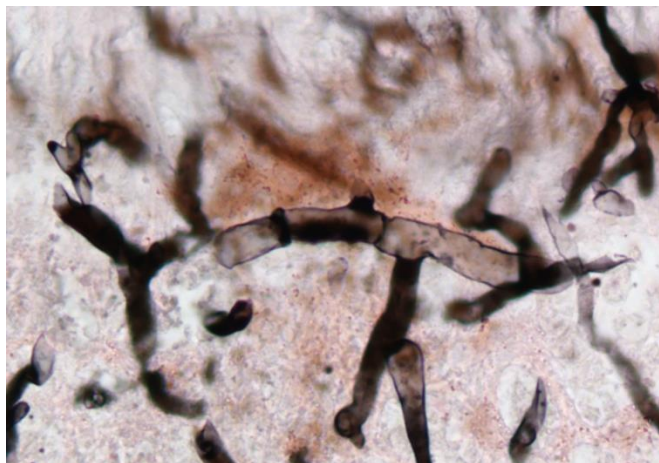
**Figure 1.** CT lung scan showing the extensive consolidation (57 x 61 mm) at the lower lobe of the left lung associated with pleural effusion.



**Figure 2.** CT lung scan showing the slight increment of the left lung consolidation (53 x 77 mm) appearing as an area of pulmonary opacity surrounded by normal parenchyma.

*tuberculosis*, GM and BDG antigen.

The patient continued to experience evening fever peaks and cough. On day 32 we repeated a CT scan showing unaltered the left lung consolidations and the left thyroid lobe lesion and an increase of the multiple nodules at the right kidney. These radiological findings were discussed in a multidisciplinary meeting with radiologists, infectivologists and pediatric hematologists discovering that the main lung lesion was presenting the reverse halo sign from the beginning. Given the lack of improvement and the severe clinical conditions, on day 36 the patient underwent left superior lung lobectomy. No postoperative complications were observed and the patient was discharged home 13 days later. The histopathological examination was consistent with a fungal pneumonia for the presence of hyphae. The identification of fungal DNA was performed by sequencing the internal transcribed spacer (ITS) domain of the rDNA gene and D1-D2 region of ribosomal sub-unites, according to the method described by White et al.<sup>9</sup> that revealed the presence of *Lichtheimia corymbifera* (**Figure 3**). Therefore, the patient



**Figure 3.** Illustration shows the microscopic examination of *Lichtheimia corymbifera*.

suspended voriconazole and received antifungal therapy with liposomal amphotericin B (5 mg/kg three times a week) and posaconazole (3 x 200 mg/d) for 7 weeks.

Six days after discharge home the patient developed low grade fever (37.5°C), painful increase and hyperemia of the left emithyroid (60 x 50 mm), increased of CRP 125 mg/l and PCT 0.13 ng/ml) with normal blood count. The patient underwent an urgent hemithyroidectomy with surgical drainage with rapid clinical improvement. The cultural search for bacteria, fungi and *Mycobacteria* resulted negative.

The patient continued a secondary prophylaxis with posaconazole (3 x 200 mg/day) for 18 months. A lung CT, performed 6 months after surgery, showed only postoperative changes whereas the renal lesion disappeared after 12 months of posaconazole treatment.

**Discussion.** This case of pulmonary mucormycosis presents two important characteristics for the clinicians. First, it shows that mucormycosis may occur also in a patient with a low risk profile. In fact, mucormycosis is a rare complication in patients with non-Hodgkin lymphoma.<sup>10</sup> Single cases of mucormycosis have been reported in patients that received immunosuppressive drug or high dose of steroids and rituximab for autoimmune disease or renal transplant.<sup>11</sup> This patient received 5 courses of immunochemotherapy where rituximab (375 mg/m<sup>2</sup>) was combined with high-dose chemotherapy containing dexamethasone (5 x 20 mg/m<sup>2</sup>/day) and anti-cancer drugs that cause often a profound neutropenia, severe mucositis, and/or enteritis.

Second, the radiological investigation showed from the beginning, when the patient was neutropenic, the presence of the reverse halo sign that was not pointed out initially by the radiologist and described instead only as lung consolidation. In fact, recent guidelines recommended strongly the search of halo sign in patients who are neutropenic or underwent

hematopoietic or solid organ transplantations, together with the number of nodular lesions and the presence of pleural effusion, to make the differential diagnosis with other fungal infections.<sup>12,13</sup> The reverse halo sign can be found in several type of infectious pneumonia (bacterial, fungal, mycobacterial, and *Pneumocystis jirovecii* pneumonia) and in different non-infectious lung diseases (lymphomatoid granulomatosis, radiation pneumonitis).

A recent study on 70 patients found that the reverse halo sign was secondary to an infectious bacterial or fungal cause in 66% of patients with hematological malignancy or who underwent stem cell transplantation while it was associated with a non-infectious cause in 70% of patients who underwent a solid organ transplantation. Interestingly, the reverse halo sign was not so specific for mucormycosis because it was described in 20% of patients with aspergillosis and 19% of patients with mucormycosis. The characteristics of halo sign, significantly associated with an infectious cause, are the presence of neutropenia, the rim thickness, the central glass attenuation and the pleural effusions.<sup>14</sup> All these radiological characteristics were present in the case described but they were initially misinterpreted as possible aspergillosis. The initial clinical response and the positivity of the BDG antigen assay contributed to address the clinical suspicion toward aspergillosis instead of another type of fungal infection. BDG assay can be found positive in different fungal or bacterial infections, whereas it is usually absent in cryptococcosis and mucormycosis. On the other hand, in mucormycosis by *Rhizopus spp*, BDG antigen assay can be positive.<sup>15</sup> BDG antigen assay has been added to the EORTC/MSG criteria for the diagnosis of invasive fungal infections but the data in pediatric populations are limited.<sup>16</sup> In our case, the transient high positivity for serum BDG antigen was interpreted as a false-positive, secondary to the administration of polyvalent IgM-enriched immunoglobulins.

In the first days of infection, the treatment was based on empirical antibiotic and antifungal treatment. The addition of micafungin was directed to cover the patient for *Candida* and *Aspergillus* and the high value of BDG antigen reinforced this therapeutic choice. Considering that BDG antigen assay cannot indicate the etiology of the infection and the presence of the reverse halo sign, we agreed retrospectively that the addition of liposomal amphotericin B would have been more indicated. Biopsy should be pursued as soon as possible, because the identification by histopathology, culture, and molecular tests lead to earlier initiation of antifungal therapy.<sup>6,13</sup>

The first-line medical treatment of mucormycosis is liposomal Amphotericin B (L-AmB) at the daily dose of 5-7.5 mg/kg or the combination of L-AmB with triazoles.<sup>6,7,17</sup>

Surgery is essential in the treatment of mucormycosis, and the highest levels of therapeutic success have been achieved when surgery was combined with medical management especially in pulmonary lesions.<sup>13</sup>

**Conclusions.** In conclusion, this case showed that also intensive chemotherapy for B-NHL may represent a risk factor for mucormycosis infection. Liposomal amphotericin B and surgery are key tools for a successful treatment of mucormycosis.

## References:

1. Bassetti M, Bouza E. Invasive mould infections in the ICU setting: complexities and solutions. *J Antimicrob Chemother.* 2017;72(Suppl 1):i39 - i47  
<https://doi.org/10.1093/jac/dkx032>  
PMid:28355466
2. Francis JR, Villanueva P, Bryant P, Blyth CC. Mucormycosis in children: review and recommendations for management. *J Pediatric Infect Dis Soc.* 2017;00:1 - 6
3. Petrikkos G, Skiada A, Lortholary O, Roilides E, Walsh TJ, Kontoyiannis DP. Epidemiology and clinical manifestations of mucormycosis. *Clin Infect Dis.* 2012; 54(Suppl.1): 23-34  
<https://doi.org/10.1093/cid/cir866>  
PMid:22247442
4. Roden MM, Zaoutis TE, Buchanan WL, Knudsen TA, Sarkisova TA, Schaufele RI, et al. Epidemiology and outcome of zygomycosis: a review of 929 reported cases. *Clin Infect Dis.* 2005; 41:634-53  
<https://doi.org/10.1086/432579>  
PMid:16080086
5. Zaoutis TE, Roilides E, Chiou CC, Buchanan WL, Knudsen TA, Sarkisova TA, et al. Zygomycosis in children: a systematic review and analysis of reported cases. *Pediatr Infect Dis J.* 2007; 26:723-7  
<https://doi.org/10.1097/INF.0b013e318062115c>  
PMid:17848885
6. Otto WR, Pahud BA, Yin DE. Pediatric Mucormycosis: A 10-Year Systematic Review of Reported Cases and Review of the Literature. *J Pediatric Infect Dis Soc.* 2019; 8:342-350  
<https://doi.org/10.1093/jpids/piz007>  
PMid:31181136
7. Muggeo P, Calore E, Decembrino N, Frenos S, De Leonardi F, Colombini A, et al. Invasive mucormycosis in children with cancer: A retrospective study from the Infection Working Group of Italian Pediatric Hematology Oncology Association. *Mycoses.* 2019;62:165-170  
<https://doi.org/10.1111/myc.12862>  
PMid:30338581
8. Mussolin L, Lovisa F, Galligani I, Cavallaro E, Carraro E, Damanti CC, et al. Minimal residual disease analysis in childhood mature B-cell leukaemia/lymphoma treated with AIEOP LNH-97 protocol with/without anti-CD20 administration. *Br J Haematol.* 2020; 189(3):e108-e111  
<https://doi.org/10.1111/bjh.16531>  
PMid:32080837
9. White TJ, Bruns TD, Lee SB, Taylor JW. Amplification and direct sequencing of fungal ribosomal RNA genes for phylogenetics. In Innis N, Gelfand J., White T, PCR Protocols: A Guide to Methods and Applications. Academic Press, New York. 1990; p. 315-322  
<https://doi.org/10.1016/B978-0-12-372180-8.50042-1>  
PMid:1696192
10. Pagano L, Offidani M, Fianchi L, Nosari A, Candoni A, Picardi M, et al. Mucormycosis in hematologic patients. *Haematologica.* 2004;89:207 - 214
11. Hung HC, Shen GY, Chen SC, Yeo KJ, Tsao SM, Lee MC, et al. Pulmonary Mucormycosis in a Patient with Systemic Lupus Erythematosus: A Diagnostic and Treatment Challenge. *Case Rep Infect Dis.* 2015;2015:478789  
<https://doi.org/10.1155/2015/478789>  
PMid:26185693 PMCID:PMC4491550
12. Cornely OA, Arian-Akdagli S, Dannaoui E, Groll AH, Lagrou K, Chakrabarti A, et al. ESCMID and ECMM joint clinical guidelines for the diagnosis and management of mucormycosis 2013. *Clin Microbiol Infect.* 2014;20 Suppl 3:5 - 26  
<https://doi.org/10.1111/1469-0691.12371>  
PMid:24479848
13. Cornely OA, Alastruey-Izquierdo A, Arenz D, Chen SCA, Dannaoui E, Hochhegger B et al. Global guideline for the diagnosis and management of mucormycosis: an initiative of the European Confederation of Medical Mycology in cooperation with the Mycoses Study Group Education and Research Consortium. *Lancet Infect Dis.* 2019;19(12):e405 - e421
14. Thomas R, Madan R, Gooptu M, Hatabu H, Hammer MM. Significance of the Reverse Halo Sign in Immunocompromised Patients. *AJR Am J Roentgenol.* 2019;213:549 - 554  
<https://doi.org/10.2214/AJR.19.21273>  
PMid:31039026
15. Angebault C, Lanternier F, Dalle F, Schimpf C, Ruopie AL, Dupuis A, et al. Prospective Evaluation of Serum  $\beta$ -Glucan Testing in Patients With Probable or Proven Fungal Diseases. *Open Forum Infect Dis.* 2016;3:ofw128  
<https://doi.org/10.1093/ofid/ofw128>  
PMid:27419189 PMCID:PMC4942764
16. De Pauw B, Walsh TJ, Donnelly JP, Stevens DA, Edwards JE, Calandra T et al. Revised definitions of invasive fungal disease from the European Organization for Research and Treatment of Cancer/Invasive Fungal Infections Cooperative Group and the National Institute of Allergy and Infectious Diseases Mycoses Study Group (EORTC/MSG) Consensus Group. *Clin Infect Dis.* 2008;46:1813 - 1821
17. Groll AH, Castagnola E, Cesaro S, Dalle JH, Engelhard D, Hope W, et al. Fourth European Conference on Infections in Leukaemia (ECIL-4): guidelines for diagnosis, prevention, and treatment of invasive fungal diseases in paediatric patients with cancer or allogeneic haemopoietic stem-cell transplantation. *Lancet Oncol.* 2014;15:e327 - e340  
[https://doi.org/10.1016/S1470-2045\(14\)70017-8](https://doi.org/10.1016/S1470-2045(14)70017-8)