



**Review Article**

**Pediatric Mastocytosis: An Update**

Fiorina Giona.

Hematology, Department of Translational and Precision Medicine, Sapienza University of Rome, Rome, Italy.

**Competing interests:** The authors declare no conflict of Interest.

**Abstract.** Mastocytosis is a rare clonal disorder characterized by excessive proliferation and accumulation of mast cells (MC) in various organs and tissues. Cutaneous mastocytosis (CM), the most common form in children, is defined when MC infiltration is limited to the skin. In adults, the most common form is systemic mastocytosis (SM), characterized by MC proliferation and accumulation in organs, such as bone marrow, lymph nodes, liver, and spleen.<sup>1</sup> Genetic aberrations, mainly the KIT D816V mutation, play a crucial role in the pathogenesis of mastocytosis, enhancing MC survival and subsequent accumulation in organs and tissues.<sup>2,3</sup> CM includes three forms: solitary mastocytoma, maculopapular cutaneous mastocytosis (MPCM), and diffuse cutaneous mastocytosis (DCM). In most children with CM, skin lesions regress spontaneously around puberty; unfortunately, it is not always a self-limiting disease.<sup>4</sup> Even if SM occurs occasionally, all children with mastocytosis require planned follow-up over time. Children with mastocytosis often suffer from MC mediator-related symptoms, the most common of which is itching, often triggered by rubbing the lesions. Management of pediatric mastocytosis is mainly based on strict avoidance of triggers. Treatment with H1 and H2 histamine receptor blockers on demand and the availability of epinephrine auto-injectors for the patients to use in case of severe anaphylactic reactions are recommended.

**Keywords:** Mastocytosis; Children; Skin involvement.

**Citation:** Giona F. Pediatric mastocytosis: an update. *Mediterr J Hematol Infect Dis* 2021, 13(1): e2021069, DOI: <http://dx.doi.org/10.4084/MJHID.2021.069>

**Published:** November 1, 2021

**Received:** September 29, 2021

**Accepted:** October 23, 2021

This is an Open Access article distributed under the terms of the Creative Commons Attribution License (<https://creativecommons.org/licenses/by-nc/4.0>), which permits unrestricted use, distribution, and reproduction in any medium, provided the original work is properly cited.

Correspondence to: Fiorina Giona, MD. Hematology, Department of Translational and Precision Medicine, Sapienza University of Rome, Via Benevento 6, 00161 Rome, Italy. Tel: +39-06-49974738. E-mail: [fiorina.giona@uniroma1.it](mailto:fiorina.giona@uniroma1.it)

**Introduction.** Mastocytosis is a rare myeloproliferative disease characterized by an increase in clonal morphologically and phenotypically abnormal mast cells (MC) that accumulate in one or more organs and/or tissues. Most commonly, MCs infiltrate the skin, the bone marrow (BM), liver, spleen, lymph nodes, and gastrointestinal tract.<sup>1-5</sup> Disease manifestations can be due to the release and activity of MC mediators and/or from the infiltration of MC within affected organs.<sup>5</sup> Traditionally, the disease is divided into cutaneous mastocytosis (CM) if MC infiltration is only localized on the skin and systemic mastocytosis (SM) if MCs infiltrate various organs, such as bone marrow, spleen,

liver, and gastrointestinal tract, and also the skin. According to the 2001 WHO classification, updated in 2008 and 2016, the diagnosis of SM can be established if at least 1 major and 1 minor, or 3 minor SM criteria, shown in **table 1**, are fulfilled.<sup>6,7</sup>

CM is predominant in children, whereas the most common form of mastocytosis in adults is SM.

In 1869, the first pediatric case of mastocytosis localized in the skin was described by Nettleship and Tay, but MC was first identified by Elrich ten years later. The term *urticaria pigmentosa* was coined by Sangster in 1878 to describe skin lesions, while the term *mastocytosis* was first used in 1936.<sup>8</sup> In 2007, an

**Table 1.** Major and minor criteria useful to establish a diagnosis of systemic mastocytosis.

MAJOR CRITERION	MINOR CRITERIA
Multifocal, dense infiltrates of MCs ( $\geq 15$ MCs in aggregates) detected in BM biopsies, and/or sections of other extracutaneous organs.	a. $>25\%$ of all MCs have atypical morphology in biopsy sections of BM, or other extracutaneous organs.
	b. Detection of KIT point mutation at codon 816 in the BM, or in another extracutaneous organ.
	c. MCs exhibit CD2, and/or CD25.
	d. Serum total tryptase $> 20$ ng/mL (no other associated myeloid neoplasm).

international Expert Working Conference provided consensus statements on diagnostic criteria for mastocytosis.<sup>9</sup> Three different forms of CM were identified: (1) solitary mastocytoma of the skin, (2) maculopapular cutaneous mastocytosis (MPCM), and (3) diffuse cutaneous mastocytosis (DCM).<sup>9</sup> In addition, this Consensus Group established diagnostic criteria to define CM: (a) the presence of a typical skin lesion (major criterion), (b) increased numbers of MCs in biopsy sections of the skin lesions (minor criterion), and (c) an activating *KIT* mutation at codon 816 in skin lesions (minor criteria).<sup>9,10,11</sup> Recently, considering the different characteristics of adulthood-onset and childhood-onset CM, an international task force revised the classification and criteria for the diagnosis of cutaneous manifestations (**Table 2**).<sup>10</sup> In particular, the MPCM subgroup was subdivided into 2 variants, namely a monomorphic variant with small maculopapular lesions, which is predominant in adult patients, and a polymorphic variant with larger lesions of variable size and shape, which is typically seen in children (**Figure 1**).

Regarding the criteria for diagnosis, Darier's sign was established as a major criterion to define CM, as it is always positive in children with CM (**Table 2**). Darier's sign is a skin change observed,

within 15-30 minutes, upon mild rubbing of the lesions. In general, the skin becomes red, swollen, and itchy due to the release of MC mediators.




**Table 2.** Diagnostic criteria for cutaneous mastocytosis.

MAJOR CRITERIA
✓ Typical skin lesions of mastocytosis.
✓ Darier's sign.
MINOR CRITERIA
✓ Increased number (at least 4-fold) of mast cells in biopsy sections of the skin lesions.
✓ (Activating) <i>KIT</i> mutation in the skin lesions.

**Epidemiology and Natural History.** Mastocytosis in the pediatric age is characterized by an almost exclusively cutaneous involvement and is considered a clonal expansion of benign nature, with spontaneous regression by puberty in more than 80% of cases. Skin lesions are located predominantly on the trunk, less frequently on the limbs, and rarely on the head.<sup>4,10,12</sup>

Even if some rare familial cases are described, pediatric mastocytosis is considered a sporadic disease, not hereditary.<sup>1</sup> Late-onset of the disease in pediatric age correlates with an increased risk of developing SM, whereas cases of aggressive neonatal mastocytosis are extremely rare.<sup>11</sup> The disease course may be characterized by the complete absence of symptoms, or alternatively by the appearance of the MC mediator-related symptoms such as itching, flushing, blisters, wheezing, abdominal pain, cramping, reflux, ulcers, diarrhea, hypotension, headache, and depression. The risk of anaphylaxis in children with mastocytosis is higher compared to the general population; however, allergic hypersensitivity to Hymenoptera venoms is less than in adults with mastocytosis. Regarding the onset age of pediatric mastocytosis, 55% of cases are diagnosed between birth to 2 years, typically in the first six months of life, 35% over 15 years of age, and the remaining 10% of cases under 15 years. In childhood mastocytosis, the male/female ratio is reported to be 1.4.<sup>11</sup>

**Clinical Presentations.** In pediatric patients, the most common symptom is itching, caused by MC degranulation and often triggered by rubbing the lesions.<sup>13</sup> Among the various cutaneous lesions shown in **Figure 1**, the MPCM is the most frequent form, detectable in about 70% of children with mastocytosis, generally younger than two years. Skin manifestations are mainly macules and papules, brownish or reddish; plaques and nodules may coexist. Lesions of the MPCM form may have either a monomorphic or, more frequently, a polymorphic appearance, the latter having a better prognosis. MPCM-large lesions generally occur under seven months of age, and MPCM-small lesions over two years of age. In children with MPCM, the disappearance of the small lesions takes longer ( $\geq 8$  years) than the large ones.<sup>13</sup> In MPCM, Darier's sign is characteristic.<sup>14</sup> Cutaneous mastocytoma, congenital or developed within the third month of life, is diagnosed in about 15% of children with mastocytosis. The term *cutaneous mastocytoma* can be used in the presence of up to three lesions that are brown/yellow and are usually localized on the trunk and limbs. If lesions are more than three, a diagnosis of MPCM is made. Mastocytoma can increase in size and change in morphology, but it does not generally increase and usually regress by puberty.<sup>10,15</sup>

<b>CUTANEOUS MASTOCYTOSIS</b>	
<i>SUBTYPE</i>	<i>VARIANT</i>
<b>MACULOPAPULAR CUTANEOUS MASTOCYTOSIS (MPCM)</b>  <b>OR</b>  <b>URTICARIA PIGMENTOSA</b>	<b>MONOMORPHIC</b>  
	<b>POLYMORPHIC</b>  
<b>DIFFUSE CUTANEOUS MASTOCYTOSIS (DCM)</b>	
<b>MASTOCITOMA</b>	

**Figure 1.** Classification of CM and characteristic skin lesions in children with mastocytosis.

Darier's sign is positive.

DCM is less common, but it is the most severe clinical presentation of CM, with MC infiltration of the entire skin (5-13%). It usually appears in very young children.

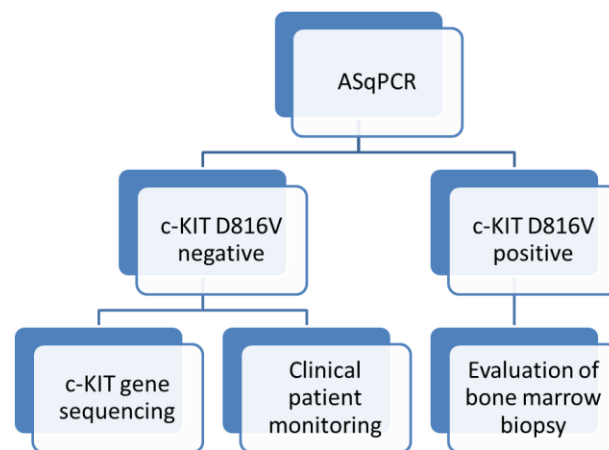
The skin is typically thickened and has a typical orange-peel appearance. Vesicles of various sizes, even giant, are frequent. DCM has an excellent chance of remission at five years, although a high mortality rate (24%),

mainly due to anaphylactic shock and digestive bleeding, is reported. It is important to avoid Darier's sign in patients with DMC, in order to minimise the potential massive release of mediators from MCs.

In most cases, marked and persistent dermographism occurs after minimal mechanical irritation.<sup>10,15</sup> Elevated tryptase levels are found in a minority of children, and systemic symptoms are not always indicative of SM.<sup>16</sup> However, it is important to consider the possibility of evolution in the systemic form. In a recent review of literature, it emerged that approximately 1/100 children with CM would develop a systemic form.<sup>15</sup>

There are little data available regarding the role of the environment or epigenetic factors in children's disease development or progression. In a study including 32 patients, it was demonstrated that some drugs, such as non-steroidal anti-inflammatory drugs (NSAIDs), beta-lactams, nifedipine, and levothyroxine, and or/and tobacco mothers chronic exposure during pregnancy, negatively influenced spontaneous disease remission in children. Surprisingly, it was found that children who achieved complete regression of the disease had a chronic dysreactive disease, usually asthma or eczema, before or after the diagnosis of mastocytosis.<sup>17</sup>

**Pathophysiology.** The pathogenesis of CM in children is still unclear. In the surface membrane, MCs express a receptor for a stem cell factor, CD117, also known as KIT. It is known that activating mutations of the gene encoding the KIT receptor (c-KIT), observed among 90% of adults with SM, play a crucial role in the pathogenesis of mastocytosis, enhancing MCs survival with subsequent accumulation of MCs in various organs and tissues.<sup>6,18,19</sup> Pediatric mastocytosis is considered a clonal disorder associated with mutations of the proto-oncogene KIT in varying ratios, from 0 to 83%.<sup>17</sup> The mutation of Kit codon 816 (D816V) in exon 17, found in 80% of cases with adult-onset disease, was found in only 42% of pediatric patients. Among children without any mutation of codon 816 (D816V, D816Y, and D816I), other mutations involving exons 8, 9, 11, and 13 were found in 44% of them by sequencing the entire KIT gene.<sup>20</sup> For this reason, in children with CM without KIT D816V mutation, sequencing the entire c-KIT gene is recommended (**Figure 2**). As a proportion of children do not show any c-KIT mutations, it is most likely that other gene mutations could be responsible for the pathogenesis of the disease.<sup>18,20</sup> The various c-KIT gene status, wild type, mutations in exon 17, and other mutations found in children do not correlate with clinical phenotypes, MPCM, DCM, and mastocytoma and do not predict the outcome of the disease.<sup>18,21-23</sup> The presence of c-KIT mutations of the MCs in the skin confirms the diagnosis of CM, but this is not a diagnostic criterion for SM nor a predictor of the evolution of the disease.<sup>2,24,25</sup> On the other hand, the presence of KIT 816V mutation in the



**Figure 2.** Diagnostic flow-chart for c-KIT mutation analysis, and bone marrow biopsy in children with mastocytosis. ASqPCR = Allele-specific quantitative PCR.

peripheral blood (PB) of children with CM should suggest performing a bone marrow biopsy, which is useful for identifying children at risk of developing SM.<sup>18,26,27</sup>

Serum tryptase levels (normal values <11.5 ng/ml), which include values of protryptase, a molecule constitutively secreted by unstimulated MCs, and mature tryptase, stored as secretory granules in cells, are considered markers of MC activity.<sup>28</sup> In the pediatric age, increased serum tryptase levels are more likely to indicate the presence of active MC in the skin.<sup>14</sup> In a recent study, children with DCM showed higher basal serum tryptase levels than those with mastocytoma and MPCM.<sup>29</sup> It emerged from a previous study that children with MPCM with smaller lesions had higher basal tryptase levels and presented a worse outcome than those with larger ones.<sup>30</sup> High levels of basal serum tryptase, combined with a skin lesion extension, in children with mastocytosis were correlated with the possibility of developing very serious symptoms due to the MC activation.<sup>31</sup> In the same study, the tryptase cut-offs useful for better managing children with mastocytosis were identified, as follows: a) 6.6 ng/ml: to start a daily anti-mediator therapy; b) 15.5 ng/ml: to hospitalize the patient; c) 30.8 ng/ml: to admit the child to an intensive care unit. In case of massive skin involvement and baseline serum tryptase values of 16 ng/ml, the initiation of intensive anti-mediator therapy is recommended to reduce anaphylactic risk.<sup>31</sup> Tryptase levels were a good predictor of pediatric anaphylactic events in a retrospective study including 102 children with CM.<sup>32</sup> In children with mastocytosis, over time, there is a progressive decrease of tryptase levels, and it has been speculated that this is probably due to pubertal hormones or physiological reduced secretory activity by MCs during puberty.

Another enzyme released from MCs is histamine (normal plasma levels in children: 0.3–1.0 ng/mL). An increase in histamine levels has been reported in children

**Table 3.** Features useful to identify subtypes and variants of CM.

FEATURES		SUBTYPE
NUMBER OF LESIONS	≤3	Mastocytoma
	>4	MPCM
APPEARANCE OF THE LESIONS	Small, round, mostly flat, brown or red maculopapular lesions.	Monomorphic variant of MPCM
	Larger, brown to red heterogeneous lesions of different sizes, with macular, papular, plaque-type or nodular aspects.	Polymorphic variant of MPCM
OVERALL SKIN APPEARANCE	Erythrodermia and generalized pachydermia (thickened skin). Extensive spontaneous blistering with erosions. Extensive bullous lesions and small vesicles.	DCM
LOCALIZATION OF THE LESIONS	Symmetrical distribution on the body, without involvement of the central face, palms, and soles of the feet.	Monomorphic variant of MPCM
	Asymmetric distribution with involvement of the head, particularly the lateral parts of the forehead, the neck and extremities.	Polymorphic variant of MPCM

with DCM; however, an absolute correlation has not been found between histamine levels and MC load in skin lesions.<sup>33</sup> Serum histamine levels in DCM patients are higher during the first two months of life but tend to decrease towards ages 9–12 months.<sup>34</sup> In another study, children with mastocytosis and high histamine levels showed more severe bone involvement and increased basal gastric acid concentration.<sup>34</sup>

Some studies were carried out on the role of some cytokines in pediatric mastocytosis. For example, increased levels of Interleukin-31 (IL-31) were associated with the presence of pruritus, and IL-6 was identified as a marker of mastocytosis severity.<sup>35</sup>

**Diagnostic Assessments.** Pediatric mastocytosis is generally limited to the skin without signs or symptoms of SM or other hematologic diseases. In clinical practice, the diagnosis of CM in children is based on the morphology of the skin lesions and the Darier's sign, considered as major criteria. An important tool to define CM subtypes is to perform a detailed evaluation of the cutaneous lesion features, including number and type, mono or polymorphic appearance, color, size, localization, and overall skin aspect (**Table 3**). Among laboratory tests, the baseline serum tryptase levels are useful to define the disease extension in children with CM, and they represent an indicator risk of anaphylaxis and other severe allergic reactions in this category of patients. It is important to consider that increased serum tryptase may occur in other diseases, such as hereditary alpha-tryptasemia, chronic eosinophilic leukemia, and nephropathies. High tryptase levels without organomegaly and/or abnormal cell count are not indicative of performing a BM evaluation.

A complete diagnostic assessment of children with CM, above all for those with severe symptoms or extensive disease, includes a careful clinical examination, complete blood cell counts, hepatic functions, and an abdominal ultrasound to evaluate organomegaly. Allele-specific quantitative PCR (ASqPCR) for KIT D816V mutation analysis in PB has been recently added to a

diagnostic algorithm for pediatric mastocytosis if organomegaly, elevated tryptase, or severe MC mediator-related symptoms are present.<sup>18,37</sup> KIT D816V mutation in PB identifies the subgroup of children who need a more in-depth follow-up, as they are at risk of SM.

Gastroscopy and colonoscopy with biopsies are indicated when gastrointestinal symptoms are present. Bone marrow biopsy is rarely needed in children with CM except when very high serum tryptase levels (>100 ng/mL) are combined with cytopenia undue to other causes but associated with organomegaly and/or gastrointestinal symptoms are present.<sup>18,37,38</sup> Once the diagnosis is established, patients could be followed according to the abnormalities detected, how recently suggested by some researchers who proposed a specific workup algorithm for children with CM.<sup>18,26,37</sup> If systemic MC mediator symptoms or extensive disease (widespread MPCM or DCM) are present, a close follow-up including abdominal ultrasound, tryptase levels, and KITD816V detection in PB are useful. The evaluation of KIT D816V mutation in PB during follow-up is of great importance to identify the subgroup of children at risk of SM who need BM investigation. Patients with isolated organomegaly, and/or high tryptase levels, and negative KIT D816V mutation should also be evaluated for other mutations in KIT (**Figure 2**).

**Management and Treatment.** Management of children with CM is aimed to prevent or control symptoms related to MC degranulation. The triggers vary in patients and can include mechanical and physical stimuli, infections, dietary, and drugs.<sup>11,18,31</sup> Avoiding extreme physical exercise, sudden temperature changes, and skin lesions friction are simple measures to prevent exacerbation.<sup>24,25</sup> Regarding dietary, various histamine-containing foods (e.g., cured meats, smoked fish, aged cheeses, fermented foods, eggplant, spinach) and histamine-releasing foods (e.g., citrus fruits, strawberries, pineapple, tomatoes, nuts, shellfish, chocolate, additives) are considered as triggers. In a recent study, the rate of vaccine reactions in children

**Table 4.** Pediatric grade scale of symptoms of mastocytosis.

<b>GRADE 0</b>	NO SYMPTOMS
<b>GRADE 1</b>	MILD SYMPTOMS, NO THERAPY REQUIRED
<b>GRADE 2</b>	MODERATE SYMPTOMS, KEPT UNDER CONTROL WITH ANTI MEDIATOR-TYPE DRUGS
<b>GRADE 3</b>	SEVERE SYMPTOMS, NOT SUFFICIENTLY CONTROLLED WITH THERAPY
<b>GRADE 4</b>	SEVERE ADVERSE EVENTS THAT REQUIRE EMERGENCY THERAPY AND HOSPITALIZATION

with mastocytosis is slightly higher than that reported in the general population (3–6%). Therefore, in children with CM, the authors recommend single-vaccine regimens and postvaccination observation for 1–2 hours, whereas vaccines should be administered on the recommended schedule in those with other cutaneous forms of mastocytosis.<sup>39</sup>

Since medications commonly used in general anesthesia can degranulate MCs, choosing anesthetic agents with a low capacity to elicit MC degranulation and a regularly scheduled antihistamine treatment are usually recommended before and after procedures.<sup>40</sup>

**Treatment.** In pediatric mastocytosis, the treatment approach is influenced by the presence and severity of symptoms caused by the release of MC mediators and by the forms of skin lesions. Considering that MPCM and mastocytoma often regress spontaneously, the use of topical and systemic medications should be avoided in these categories of otherwise asymptomatic patients.<sup>18,41</sup> The severity of symptoms due to MC degranulation has been graded in order to permit the choice of appropriate treatment (**Table 4**). The Standard Consensus Guidelines have established a 4-grade scale for adults with mastocytosis, and it is also useful for therapeutic choice and for monitoring the risk of possible systemic evolution in children.<sup>10,42</sup>

*Systemic treatment of symptoms.* Treatment of symptoms caused by the release of MC mediators is the main goal in managing patients with CM, including children. The severity, type, and frequency of symptoms must be considered to choose the therapeutic approach. H1-antihistamines, continuously given orally, are recommended as first-line treatment and can be used on-demand in children with less frequent symptoms. The second generation, non-sedating H1-antihistamines, are preferred for patients with frequent and/or problematic manifestations. In case of persistence of the symptoms, it is advisable to add an H2 antihistamine or anti-leukotriene (Montelukast).<sup>43</sup> H2-antagonists (e.g., ranitidine), or proton pump inhibitors (e.g., omeprazole, pantoprazole, lansoprazole), are indicated in case of gastrointestinal symptoms as cramps and diarrhea.

The oral use of sodium cromoglycate to control gastrointestinal manifestations is currently controversial because comprehensive data on its mechanism of action is lacking.

The use of systemic corticosteroids, limited by numerous side effects, is indicated as a short course in children with extremely severe mediator-related symptoms and extensive and persistent blistering.<sup>18,41,44,45</sup>

*Treatment of anaphylaxis.* The risk of anaphylaxis in children with mastocytosis is 5-10%. Therefore, preventing or eliminating triggers for anaphylaxis is the main goal. The exact indications of self-injectable epinephrine have been the subject of debate; however, its prescription is recommended in children with extensive skin mastocytosis, blistering, previous episodes of anaphylaxis, and/or elevated serum tryptase levels. The dose of epinephrine should be prescribed according to children's body weight: 0.1 mg, 0.15 mg, 0.3 mg to a child weighing 7.5–15 kg, 15–30 kg, >35 kg, respectively. If necessary, epinephrine could also be used for infants at a dose of 0.15 mg or 0.1 mg to a child weighing <15 kg or <7.5 kg, respectively.<sup>46-48</sup>

*Topical treatment.* Topical corticosteroids have always been by far the most widely used, especially in patients with frequent blistering. However, their long-term use is contraindicated due to the side effects on the skin (atrophy) and adrenocortical suppression.<sup>49</sup> Instead of corticosteroids, local application of pimecrolimus is recommended in pediatric CM due to its excellent results and safety profiles.<sup>18,50,51</sup> Pimecrolimus is a calcineurin inhibitor with significant anti-inflammatory activity by blocking T-cell activation, inhibiting inflammatory cytokine synthesis, and immunomodulatory effects with a low systemic immunosuppressive potential. Disodium cromoglycate at a 1% to 4% concentration in an aqueous solution or mixed with a water-based emollient cream may decrease itching.<sup>49,52,53</sup> The use of phototherapy or photochemotherapy is not recommended in children due to the potential carcinogenic effect. In cases with diffuse localization, Narrow-band UVB rays (NB-UVB), UVA1, UVA rays with psoralen (PUVA) therapy can be employed. The use of lasers is very limited. Radical surgical excision is the extreme option in solitary mastocytoma with high mediator release and a high risk of anaphylaxis.<sup>18,41</sup>

*Innovative therapies.* Several target drugs have been tested in pediatric mastocytosis. Omalizumab, a recombinant humanized monoclonal antibody that

blocks the binding of IgE to the FcεRI receptor on the surface of MCs, showed a rapid and long-term efficacy to control severe MC-related symptoms in an adolescent with frequent episodes of anaphylaxis.<sup>54</sup> Among kinase inhibitors (KI) with activity against MC carrying D816V and other KIT mutations, midostaurin, a multi-kinase inhibitor, is indicated to treat aggressive SM in patients with D816V or wild type KIT. In childhood mastocytosis, midostaurin was successfully used in an infant with indolent SM associated with severe blistering who previously failed conventional treatments.<sup>55</sup>

Tyrosine kinase inhibitors (TKI), imatinib and masatinib, have different therapeutic indications. However, the FDA approved imatinib's use in patients with SM and KIT mutations outside of the exon 17, in the regulatory site (extracellular and juxtamembrane portions of the gene), or with unknown mutations.<sup>49</sup> Masatinib, a new highly selective TKI, targets wild-type KIT, LYN, and FYN kinases that play a crucial role in the pathogenesis of mastocytosis and could be effective in refractory cases with mutations on the regulatory site

of c-KIT. In addition, miltefosine is a promising modulator of lipid rafts for topical use.<sup>41</sup>

**Closing Remarks.** Pediatric forms of mastocytosis generally have a cutaneous presentation and regress spontaneously with age. Acquired KIT receptor mutations, less frequent in children than in adults, do not seem to be the only factor responsible for triggering MC neoplastic transformation and do not influence the development of the different clinical forms. New molecular investigation techniques, including the Next Generation Sequencing (NGS) method, may help identify other specific gene aberrations, potentially useful to define alternative therapeutic targets in forms of mastocytosis that require treatment.

**Acknowledgments.** I thank Gianluca Signoretta, a graduating student who performed the literature review for his dissertation; Martina Rousseau MD, who reviewed the dissertation and Simona Bianchi MD, who reviewed the references.

## References:

- Valent P, Horny HP, Escribano L, Longley BJ, Li CY, Schwartz LB, Marone G, Nuñez R, Akin C, Sotlar K, Sperr WR, K Wolff, R D Brunning, R M Parwaresch, K F Austen, K Lennert, D D Metcalfe, J W Vardiman, J M Bennett. Diagnostic criteria and classification of mastocytosis: A consensus proposal. *Leuk Res.* 2001; 25:603-25.  
[https://doi.org/10.1016/S0145-2126\(01\)00038-8](https://doi.org/10.1016/S0145-2126(01)00038-8)
- Verzijl A, Heide R, Oranje AP, van Schaik RHN. C-kit Asp-816-Val mutation analysis in patients with mastocytosis. *Dermatology.* 2007; 214:15-20.  
<https://doi.org/10.1159/000096907>  
PMid:17191042
- Arock M, Sotlar K, Akin C, Broesby-Olsen S, Hoermann G, Escribano L, Kristensen TK, Kluijn-Nelemans HC, Hermine O, Dubreuil P, Sperr WR, Hartmann K, Gotlib J, Cross NC, Haferlach T, Garcia-Montero A, Orfao A, Schwaab J, Triggiani M, Horny HP, Metcalfe DD, Reiter A, Valent P. KIT mutation analysis in Mast Cell Neoplasms: Recommendations of European Competence Net-work on Mastocytosis. *Leukemia.* 2015;29:1223-32.  
<https://doi.org/10.1038/leu.2015.24>  
PMid:25650093 PMCid:PMC4522520
- Meni C, Bruneau J, Gerogin-Lavialle S, Le Saché de Peuffeilhoux L, Damaj G, Hadj-Rabis S, Fraitag S, Dubreuil P, Hermine O, Bodemer C. Pediatric mastocytosis: A systematic review of 1747 cases. *Dr J Dermatol.* 2015; 172:642-51.  
<https://doi.org/10.1111/bjd.13567>  
PMid:25662299
- Lange M, Hartmann K, Carter MC, Siebenhaar F, Alvarez-Twose I, Torrado I, Brockow K, Ren-ke J, Irga-Jaworska N, Plata-Nazar K, Ługowska-Umer H, Czarny J, Belloni Fortina A, Caroppo F, Nowicki RJ, Nedoszytko B, Nedoszytko M, Valent P.. Molecular background, clinical features and management of pediatric mastocytosis: status 2021. *Internat J Molec Sciences.* 2021; 22:2586.  
<https://doi.org/10.3390/ijms22052586>  
PMid:33806685 PMCid:PMC7961542
- Valent P, Akin C, Metcalfe DD. Mastocytosis: 2016 updated WHO classification and novel emerging treatment concepts. *Blood.* 2017; 129:1420-1427.  
<https://doi.org/10.1182/blood-2016-09-731893>  
PMid:28031180 PMCid:PMC5356454
- Hartmann K, Valent P, Horny HP. Cutaneous mastocytosis. In *World Health Organization (WHO) Classification of Skin Tumours*, 4th ed.; Elder, D.E., Massi, D., Scolyer, R., Willemze, R., Eds.; International Agency for Research on Cancer: Lyon, France, 2018; pp. 275-278.
- Mutter RD, Tannemaum M, Ulmann JE. Systemic mast cell disease. *Ann Intern Med.* 1963; 59:887-906.  
<https://doi.org/10.7326/0003-4819-59-6-887>  
PMid:14082741
- Valent P, Akin C, Escribano L, Födinger M, Hartmann K, Brockow K, Castells M, Sperr W.R., Kluijn-Nelemans H.C.; Hamdy, N.A.; et al. Standards and standardization in mastocytosis: Consensus statements on diagnostics, treatment recommendations and response criteria. *Eur. J. Clin. Investig.* 2007, 37, 435-453.  
<https://doi.org/10.1111/j.1365-2362.2007.01807.x>  
PMid:17537151
- Hartmann K, Escribano L, Grattan C, Brockow K, Carter MC, Alvarez-Twose I, Matito A, Broesby-Olsen S, Siebenhaar F, Lange M, Nedoszytko M, Castells M, Oude Elberink JNG, Bo-nadonna P, Zanotti R, Hornick JL, Torreló A, Grabbe J, Rabenhorst A, Nedoszytko B, Butterfield JH, Gotlib J, Reiter A, Radia D, Hermine O, Sotlar K, George TI, Kristensen TK, Kluijn-Nelemans HC, Yavuz S, Hägglund H, Sperr WR, Schwartz LB, Triggiani M, Maurer M, Nilsson G, Horny HP, Arock M, Orfao A, Metcalfe DD, Akin C, Valent P. Cutaneous manifestations in patients with mastocytosis: Consensus report of the European Competence Network on Mastocytosis; the American Academy of Allergy, Asthma & Immunology; and the European Academy of Allergy and Clinical Immunology. *J Allergy Clin Immunol.* 2016; 137:35-45.  
<https://doi.org/10.1016/j.jaci.2015.08.034>  
PMid:26476479
- Klaiber N, Kumar S, Irani AM. Mastocytosis in Children. *Curr Allergy Asthma Reports.* 2017; 17:80.  
<https://doi.org/10.1007/s11882-017-0748-4>  
PMid:28988349
- Lange M, Nedoszytko M, Renke J, Nedoszytko B. Clinical aspects of pediatric mastocytosis: A review of 101 cases. *J Eur Acad Dermatol Venereol.* 2013; 27:97-102.  
<https://doi.org/10.1111/j.1468-3083.2011.04365.x>  
PMid:22126331
- Wiechers T, Rabenhorst A, Schick T, Preussner M, Förster A, Valent P, Horny P, Sotlar K, Hartmann K. Large maculopapular cutaneous lesions are associated with favorable outcome in childhood-onset mastocytosis. *Journal of Allergy and Clinical Immunology.* 2015; 136:1581-90.  
<https://doi.org/10.1016/j.jaci.2015.05.034>  
PMid:26152315
- Matito A, Azaña JM, Torreló A, Alvarez-Twose I. Cutaneous Mastocytosis in Adults and Children: New Classification and Prognostic Factors. *Immunol Allergy Clin N Am.* 2018; 38:351-63.  
<https://doi.org/10.1016/j.iac.2018.04.001>  
PMid:30007456

15. Lange M, Niedoszytko M, Nedoszytko B, Łata J, Trzeciak M, Biernat W. Diffuse cutaneous mastocytosis: Analysis of 10 cases and a brief review of the literature. *J Eur Acad Dermatol Vene-reol.* 2012; 26:1565-71. <https://doi.org/10.1111/j.1468-3083.2011.04350.x> PMID:22092511
16. Sadaf H. Hussain: Pediatric mastocytosis, *Curr Opin Pediatr* 2020, 32:531-538 <https://doi.org/10.1097/MOP.0000000000000922> PMID:32692050
17. Ertugrul A, Bostanci I, Kaymak AO, Gurkan A, Ozmen S. Pediatric cutaneous mastocytosis and c-KIT mutation screening. *Allergy Asthma Proc.* 2019; 40:123-128. <https://doi.org/10.2500/aap.2019.40.4201> PMID:30819282
18. Lange M, Hartmann K, Carter MC, Siebenhaar F, Alvarez-Twose I, Torrado I, Brockow K, Renke J, Irga-Jaworska N, Plata-Nazar K, Ługowska-Umer H, Czarny J, Belloni Fortina A, Caroppo F, Nowicki RJ, Nedoszytko B, Nedoszytko M, Valent P. Molecular background, clinical features and management of pediatric mastocytosis: status 2021, *International Journal of Molecular Sciences*, 2021; 22, 2586. <https://doi.org/10.3390/ijms22052586> PMID:33806685 PMCid:PMC7961542
19. Pardoning, A. Systemic mastocytosis in adults: 2019 update on diagnosis, risk stratification and management. *Am. J. Hematol.* 2018; 94, 363-377. <https://doi.org/10.1002/ajh.25292> PMID:30328142
20. Bodemer, C.; Hermine, O.; Palmérini, F.; Yang, Y.; Grandpeix-Guyodo, C.; Leventhal, P.S.; Hadj-Rabia, S.; Nasca, L.; Georgin-Lavialle, S.; Cohen-Akenine, A.; et al. Pediatric mastocytosis is a clonal disease associated with D816V and other activating c-KIT mutations. *J. Investig. Dermatol.* 2010; 130, 804-815. <https://doi.org/10.1038/jid.2009.281> PMID:19865100
21. Méni, C.; Georgin-Lavialle, S.; Le Saché de Peuffeilhoux, L.; Jais, J.P.; Hadj-Rabia, S.; Bruneau, J.; Fraïtag, S.; Hanssens, K.; Dubreuil, P.; Hermine, O.; et al. Paediatric mastocytosis: Long-term follow-up of 53 patients with whole sequencing of KIT. A prospective study. *Br. J. Dermatol.* 2018, 179, 925-932. <https://doi.org/10.1111/bjd.16795> PMID:29787623
22. Yang Y, Létard S, Borge L, Chaix A, Hanssens K, Lopez S, Vita M, Finetti P, Birnbaum D, Bertucci F, Sophie Gomez, Paulo de Sepulveda, Patrice Dubreuil. Pediatric mastocytosis-associated KIT extracellular domain mutations exhibit different functional and signaling properties compared with KIT-phosphotransferase domain mutations. *Blood.* 2010; 116:1114-23. <https://doi.org/10.1182/blood-2009-06-226027> PMID:20484085
23. Li Y, Li X, Liu X, Kang L, Liu X. Genotypic and phenotypic characteristics of Chinese neo-nates with cutaneous mastocytosis: A case report and literature review. *J Int Med Res.* 2020;48:300060520952621. <https://doi.org/10.1177/0300060520952621> PMID:32883129 PMCid:PMC7479863
24. Azan JM, Torrelo A, Matito A. Update on mastocytosis (part 2): Categories, Prognosis, and Treatment. *Actas Dermo-Sifiliogr.* 2016; 107:15-22. <https://doi.org/10.1016/j.adengl.2015.11.002>
25. Castells M, Butterfield J. Mast cell activation syndrome and mastocytosis: Initial treatment options and long-term management. *J Allergy Clin Immunol Pract.* 2019; 7:1097-1106. <https://doi.org/10.1016/j.jaip.2019.02.002> PMID:30961835
26. Carter MC, Bai Y, Ruiz-Esteves KN, Scott LM, Cantave D, Bolan H, Eisch R, Sun X, Hahn J, Maric I, Metcalfe DD. Detection of KIT D816V in peripheral blood of children with manifestations of cutaneous mastocytosis suggests systemic disease. *Br J Haematol.* 2018; 183:775-82. <https://doi.org/10.1111/bjh.15624> PMID:30488427
27. Czarny J, Zuk M, Zawrocki A, Plata-Nazar K, Biernat W, Nedoszytko M, Ługowska-Umer H, Nedoszytko B, Wasag B, Nowicki RJ, Lange M. New Approach to Paediatric Mastocytosis: Implications of KIT D816V Mutation Detection in Peripheral Blood. *Acta Dermato-Venereol.* 2020;100:adv00149. <https://doi.org/10.2340/00015555-3504> PMID:32399575
28. Álvarez-Twose, I.; Jara-Acevedo, M.; Morgado, J.M.; García-Montero, A.; Sánchez-Muñoz, L.; Teodósio, C.; Matito, A.; Mayado, A.; Caldas, C.; Mollejo, M.; et al. Clinical, immunophenotypic, and molecular characteristics of well-differentiated systemic mastocytosis. *J. Allergy Clin. Immunol.* 2016, 137, 168-178.e1. <https://doi.org/10.1016/j.jaci.2015.05.008> PMID:26100086
29. Seth N, Tuano KT, Buheis M, Chan A, Chinen J. Serum tryptase levels in pediatric mastocytosis and association with systemic symptoms. *Ann Allergy Asthma Immunol.* 2020; 125:219-21. <https://doi.org/10.1016/j.anai.2020.04.021> PMID:32371241
30. Barnes M, Van L, De Long L, Lawley LP. Severity of cutaneous findings predict the presence of systemic symptoms in pediatric maculopapular cutaneous mastocytosis. *Pediatr Dermatol.* 2014; 31:271-75. <https://doi.org/10.1111/pde.12291> PMID:24612340
31. Alvarez-Twose, I.; Vañó-Galván, S.; Sánchez-Muñoz, L.; Morgado, J.M.; Matito, A.; Torrelo, A.; Jaén, P.; Schwartz, L.B.; Orfao, A.; Escribano, L. Increased serum baseline tryptase levels and extensive skin involvement are predictors for the severity of mast cell activation episodes in children with mastocytosis. *Allergy* 2012, 67, 813-818. <https://doi.org/10.1111/j.1398-9995.2012.02812.x> PMID:22458675 PMCid:PMC3349769
32. Lange M, Zawadzka A, Schrörs S, Słomka J, Ługowska-Umer H, Nedoszytko B, Nowicki R. The role of serum tryptase in the diagnosis and monitoring of pediatric mastocytosis: A single-center experience. *Adv Dermatol Alergol.* 2017; 34:306-12. <https://doi.org/10.5114/ada.2017.69308> PMID:28951704 PMCid:PMC5560177
33. Kettelhut, B.V.; Metcalfe, D.D. Mastocytosis. *J. Invest. Dermatol.* 1991, 96, 115S-118S. <https://doi.org/10.1111/1523-1747.ep12468942> PMID:16799603
34. Belhocine W, Ibrahim Z, Grandné V, Buffat C, Robert P, Gras D, Cleach I, Bongrand P, Carayon P, Vitte J. Total serum tryptase levels are higher in young infants. *Pediatr Allergy Immunol.* 2011; 22(6):600-7. <https://doi.org/10.1111/j.1399-3038.2011.01166.x> PMID:21736626
35. Brockow, K.; Akin, C.; Huber, M.; Metcalfe, D.D. IL-6 levels predict disease variant and extent of organ involvement in patients with mastocytosis. *Clin. Immunol.* 2005; 115, 216-223. <https://doi.org/10.1016/j.clim.2005.01.011> PMID:15885646
36. Hartmann K, Escribano L, Grattan C, et al. Cutaneous manifestations in patients with mastocytosis: consensus report of the European Competence Network on Mastocytosis; the American Academy of Allergy, Asthma & Immunology; and the European Academy of Allergy and Clinical Immunology. *J Allergy Clin Immunol.* 2016; 137:35-45. <https://doi.org/10.1016/j.jaci.2015.08.034> PMID:26476479
37. Hussain, S.H. Pediatric mastocytosis. *Curr. Opin. Pediatr.* 2020; 32, 531-538. <https://doi.org/10.1097/MOP.0000000000000922> PMID:32692050
38. Lange, M.; Ługowska-Umer, H.; Nedoszytko, M.; Wasag, B.; Limon, J.; Z'awrocki, A.; Nedoszytko, B.; Sobjanek, M.; Plata-Nazar, K.; Nowicki, R. Diagnosis of Mastocytosis in Children and Adults in Daily Clinical Practice. *Acta Dermato-Venereol.* 2016; 96:292-297. <https://doi.org/10.2340/00015555-2210> PMID:26270728
39. Carter MC, Metcalfe DD, Matito A, Escribano L, Butterfield JH, Schwartz LB, Bonadonna P, Zanotti R, Triggiani M, Castells M, Brockow K. Adverse reactions to drugs and biologics in patients with clonal mast cell disorders: a group report of the Mast Cells Disorder Committee, American Academy of Allergy and Immunology. *J Allergy Clin Immunol.* 2019; 143:880-93. <https://doi.org/10.1016/j.jaci.2018.10.063> PMID:30528617
40. Hermans MAW, Arends NJT, Gerth van Wijk R, van Hagen PM, Kluijn-Nelemans HC, Oude Elberink HNG, Pasmans SGMA, van Daele PLA. Management around invasive procedures in mastocytosis: an update. *Ann Allergy Asthma Immunol.* 2017; 119:304-9. <https://doi.org/10.1016/j.anai.2017.07.022> PMID:28866309
41. Czarny, J.; Lange, M.; Ługowska-Umer, H.; Nowicki, R.J. Cutaneous mastocytosis treatment: Strategies, limitations, and perspectives. *Adv. Dermatol. Alergol.* 2018; 6, 541-545. <https://doi.org/10.5114/ada.2018.77605>



- PMid:30618520 PMCID:PMC6320483
42. Torrello, A.; Alvarez-Twose, I.; Escribano, L. Childhood mastocytosis. *Curr. Opin. Pediatr.* 2012; 24, 480-486. <https://doi.org/10.1097/MOP.0b013e328355b248> PMid:22790101
43. Turner PJ, Kemp AS, Rogers M, Mehr S. Refractory symptoms successfully treated with leuko-triene inhibition in a child with systemic mastocytosis. *Pediatr Dermatol.* 2012; 29:222-3. <https://doi.org/10.1111/j.1525-1470.2011.01576.x> PMid:22044360
44. Broesby Broesby-Olsen, S.; Dybedal, I.; Gülen, T.; Kristensen, T.K.; Møller, M.B.; Ackermann, L.; Sääf, M.; Karlsson, M.A.; Agertoft, L.; Brixen, K.; et al. Multidisciplinary Management of Mastocytosis: Nordic Expert Group Consensus. *Acta Dermato-Venereol.* 2016; 96, 602-612. <https://doi.org/10.2340/00015555-2325> PMid:26694951
45. Siebenhaar, F.; Akin, C.; Bindslev-Jensen, C.; Maurer, M.; Broesby-Olsen, S. Treatment strategies in mastocytosis. *Immunol. Allergy Clin. N. Am.* 2014, 34; 433-447. <https://doi.org/10.1016/j.jac.2014.01.012> PMid:24745685
46. González de Olano, D.; de la Hoz Caballer, B.; Núñez López, R.; Sánchez Muñoz, L.; Cuevas Agustín, M.; Diéguez, M.C.; Alvarez Twose, I.; Castells, M.C.; Escribano Mora, L. Prevalence of allergy and anaphylactic symptoms in 210 adult and pediatric patients with mastocytosis in Spain: A study of the Spanish network on mastocytosis (REMA). *Clin. Exp. Allergy* 2007; 37, 1547-1555. <https://doi.org/10.1111/j.1365-2222.2007.02804.x> PMid:17883734
47. Brockow, K.; Jofer, C.; Behrendt, H.; Ring, J. Anaphylaxis in patients with mastocytosis: A study on history, clinical features and risk factors in 120 patients. *Allergy* 2008; 63, 226-232. <https://doi.org/10.1111/j.1398-9995.2007.01569.x> PMid:18186813
48. Matito, A.; Carter, M. Cutaneous and systemic mastocytosis in children: A risk factor for anaphylaxis? *Curr Allergy Asthma Rep.* 2015; 15, 22. <https://doi.org/10.1007/s11882-015-0525-1> PMid:26139333
49. Klaiber, N., Kumar, S., & Irani, A.-M. (2017). Mastocytosis in Children. *Current Allergy and Asthma Reports*, 17(11). Doi :10.1007/s11882-017-0748-4. <https://doi.org/10.1007/s11882-017-0748-4> PMid:28988349
50. Mashiah, J.; Harel, A.; Bodemer, C.; Hadj-Rabia, S.; Goldberg, I.; Sprecher, E.; Kutz, A. Topical pimecrolimus for pediatric cutaneous mastocytosis. *Clin. Exp. Dermatol.* 2018; 43, 559-565. <https://doi.org/10.1111/ced.13391> PMid:29460435
51. Correia, O.; Duarte, A.; Quirino, P.; Azevedo, R.; Delgado, L. Cutaneous mastocytosis: Two pediatric cases treated with topical pimecrolimus. *Dermatol. Online J.* 2010; 16, 8. <https://doi.org/10.5070/D30FK211ZH> PMid:20492825
52. Edwards, A.M.; Capková, S. Oral and topical sodium cromoglicate in the treatment of diffuse cutaneous mastocytosis in an infant. *BMJ Case Rep.* 2011; 2011, bcr0220113910. <https://doi.org/10.1136/bcr.02.2011.3910> PMid:22693187 PMCID:PMC3128352
53. Vieira Dos Santos, R.; Magerl, M.; Martus, P.; Zuberbier, T.; Church, M.K.; Escribano, L.; Maurer, M. Topical sodium cromoglicate relieves allergen- and histamine-induced dermal pruritus. *Br. J. Dermatol.* 2010; 162, 674-676. <https://doi.org/10.1111/j.1365-2133.2009.09516.x> PMid:19785618
54. Matito, A.; Blázquez-Goñi, C.; Morgado, JM; Alvarez-Twose, I; Mollejo, M; Sánchez-Muñoz, L; Escribano, L. Short-term omalizumab treatment in an adolescent with cutaneous mastocytosis. *Ann Allergy Asthma Immunol.* 2013; 111:425-6. <https://doi.org/10.1016/j.anai.2013.08.014> PMid:24125156
55. Liu M, Kohn L, Roach G, et al. Treatment of systemic mastocytosis in an infant with midostaurin. *J Allergy Clin Immunol Pract.* 2019; 7(2929-31):e1. <https://doi.org/10.1016/j.jaip.2019.05.032> PMid:31154031